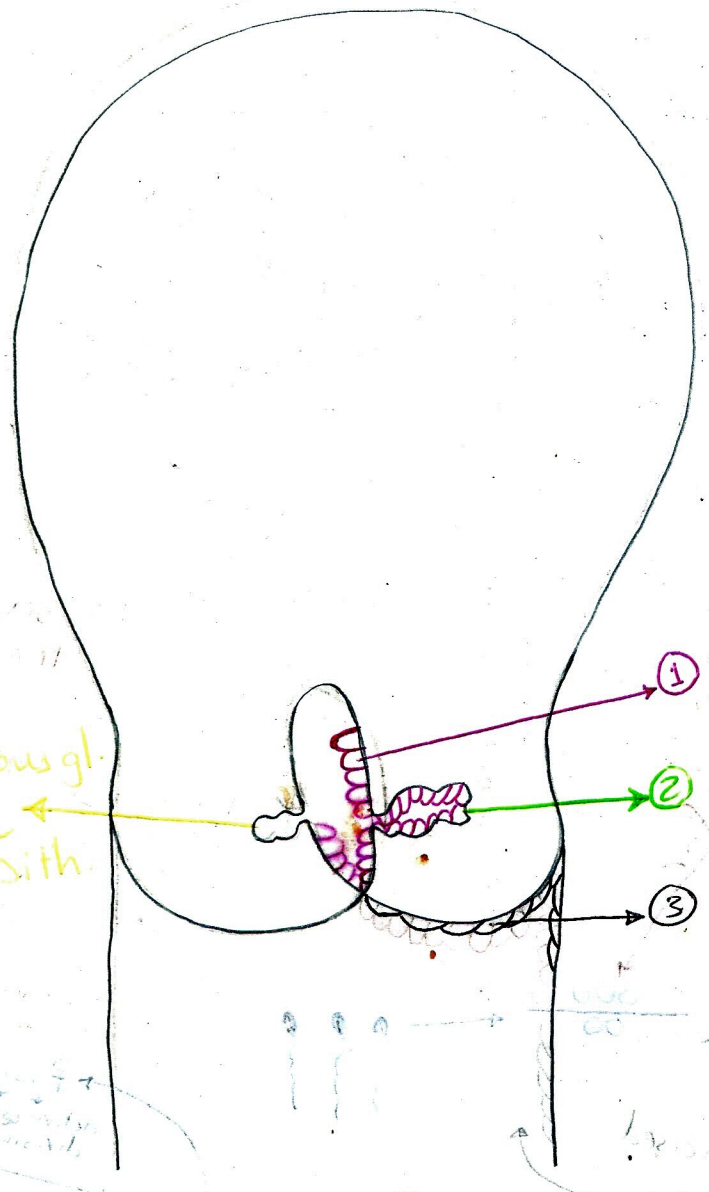
① Columnar epith. of endocervix.
② Portio Vaginalis
③ Stratified Sq. epith of ectocervix
Cervical mucous gl. lined with Columnar epith.

Adult ♀

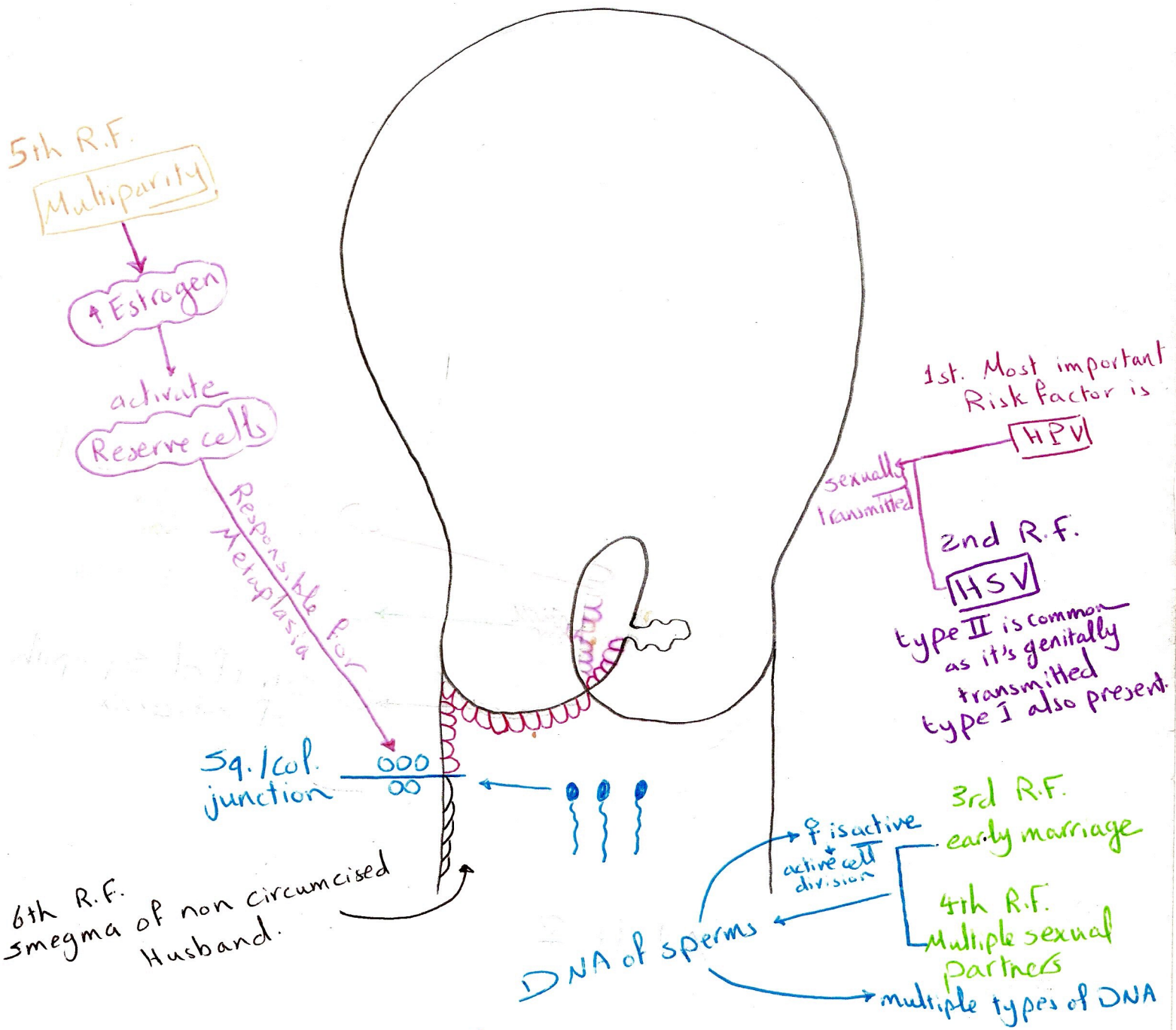
5th R.F.
Multiparity
↑ Estrogen
activate
Reserve cells
Responsible for Metaplasia
Sq./col. junction
6th R.F.
smegma of non circumcised Husband.
1st. Most important Risk factor is
HPV
sexually transmitted
2nd R.F.
HSV
type II is common as it's genitally transmitted
type I also present.
3rd R.F.
early marriage
4th R.F.
Multiple sexual partners
♀ is active
active cell division
DNA of sperms
multiple types of DNA
7th R.F.
↓ immunity by
imm. Deficiency
smoking
steroid therapy if prolonged.

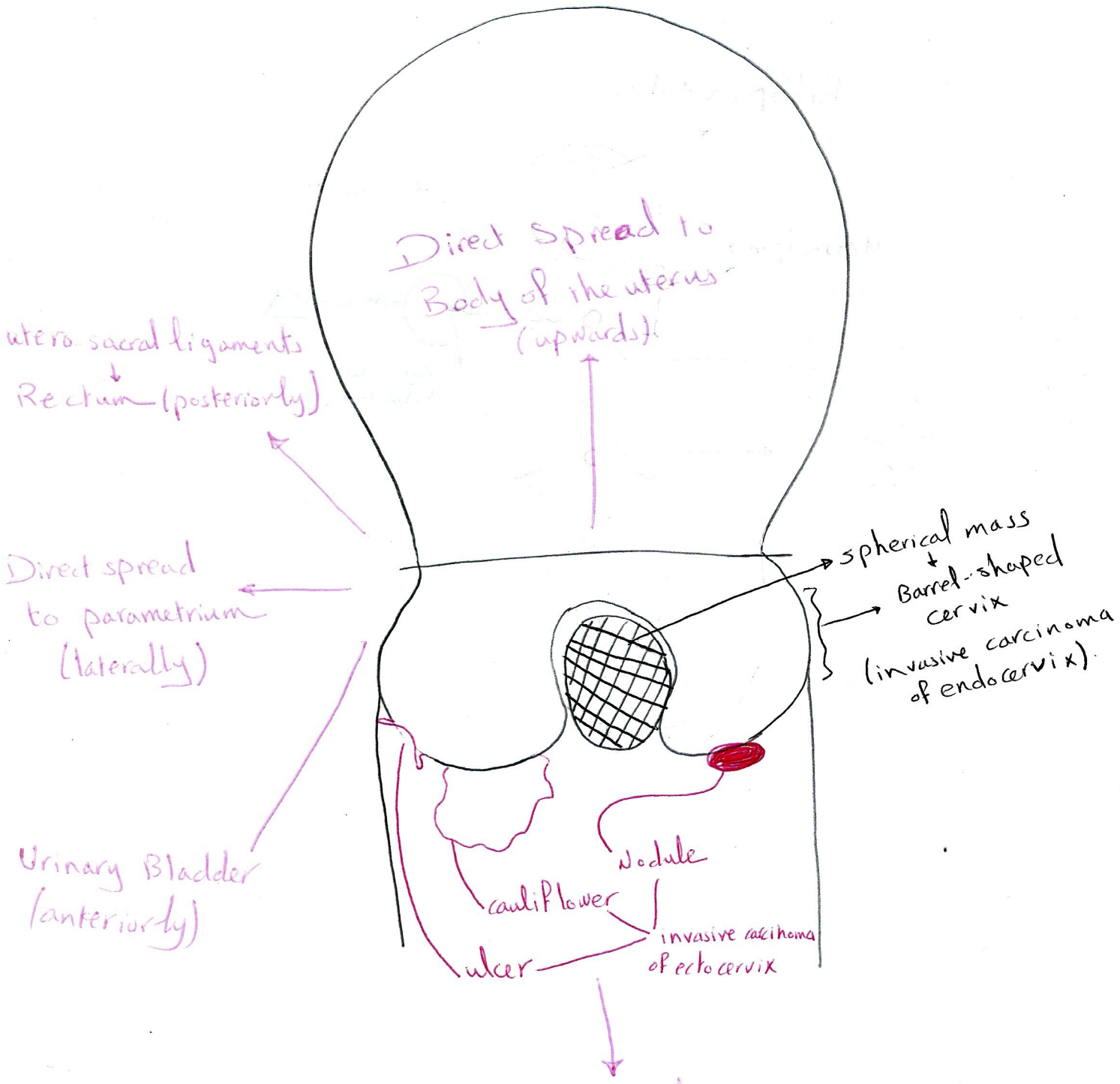
Direct Spread to Body of the uterus (upwards)
utero-sacral ligaments
Rectum (posteriorly)
Direct spread to parametrium (laterally)
Urinary Bladder (anteriorly)
spherical mass
Barrel-shaped cervix
(invasive carcinoma of endocervix)
Nodule
cauliflower
ulcer
invasive carcinoma of ectocervix
Direct spread to Vagina (Downwards)

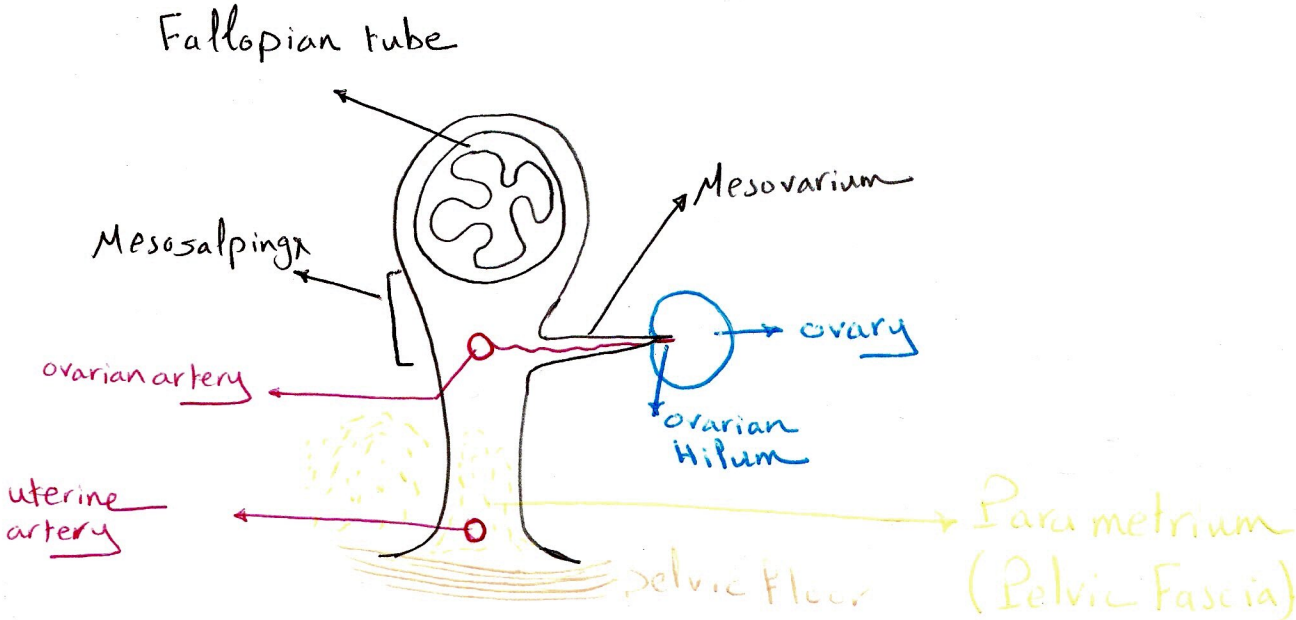
Fallopian tube
Mesovarium
Mesosalpinx
ovary
ovarian artery
ovarian Hilum
uterine artery
Parametrium
(Pelvic Fascia)
pelvic floor

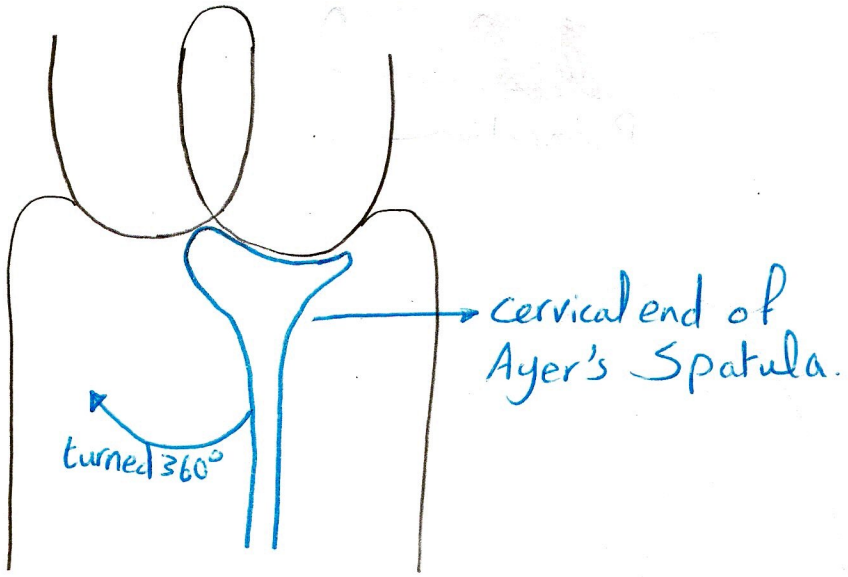

Pap Smear

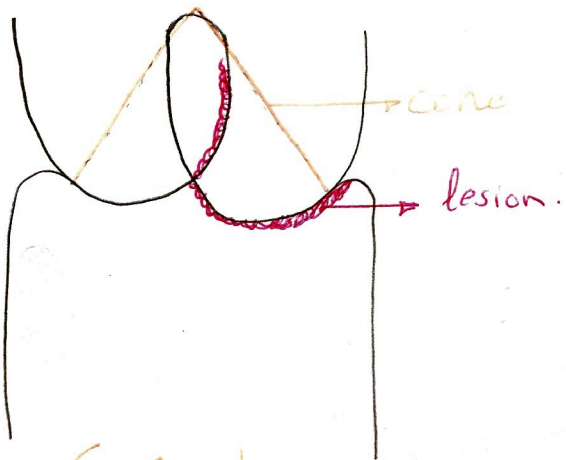

Conization

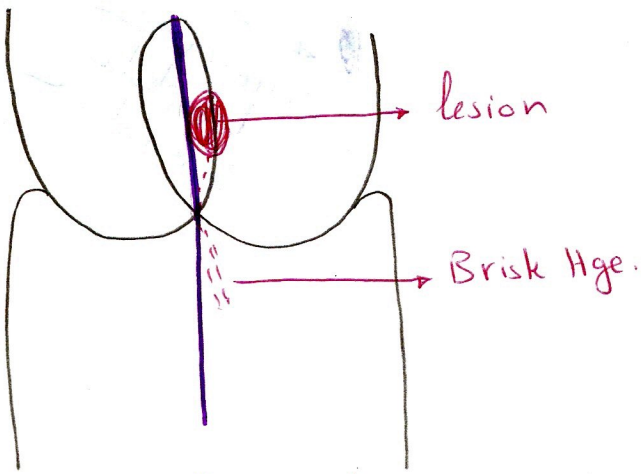

Sounding test

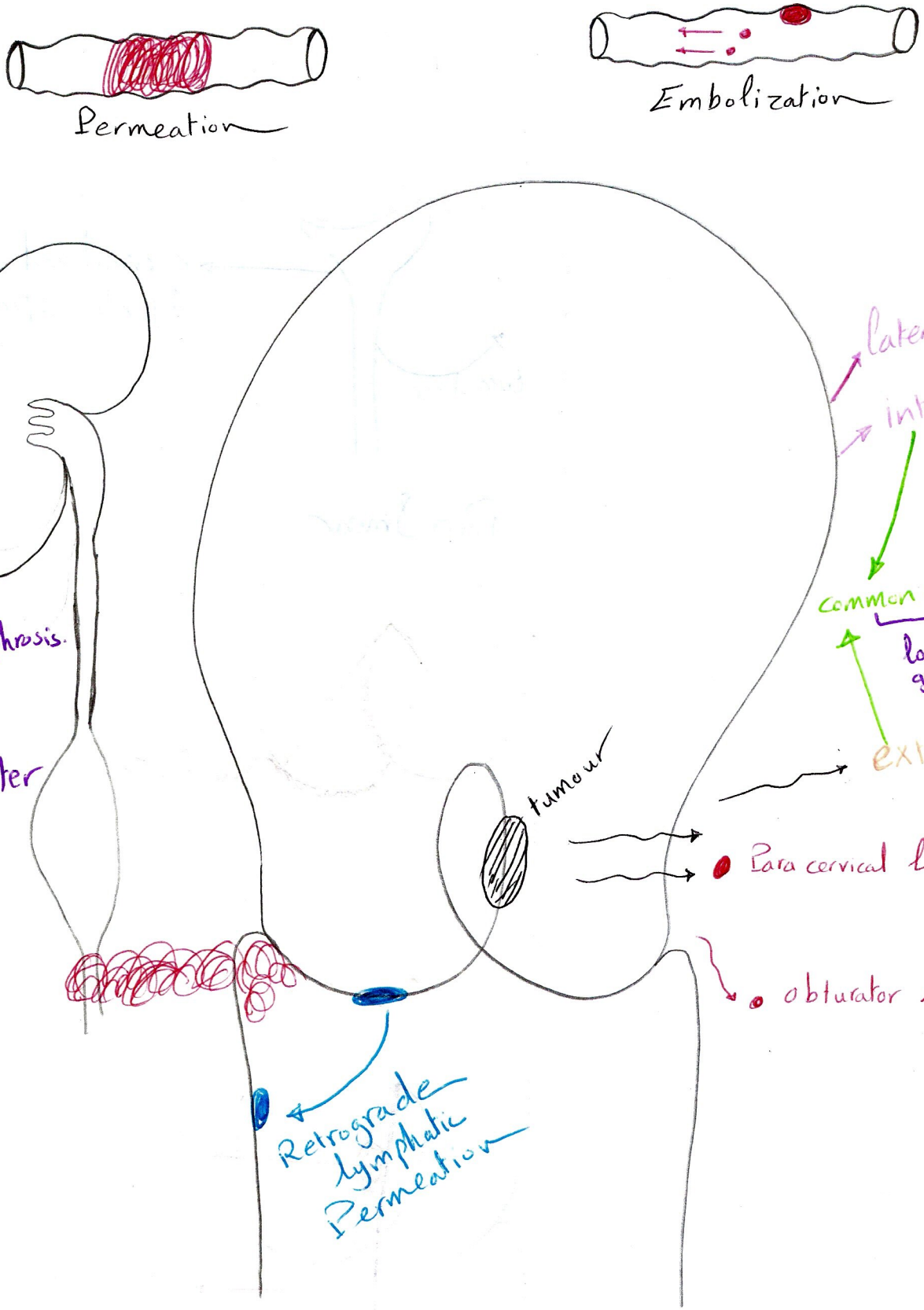
Permeation
Embolization
lateral sacral
internal iliac
common iliac L.N
lower abdominal group of aortic L.N.
external iliac
Hydronephrosis
Hydroureter
tumour
Para cervical L.N.
obturator L.N.
Retrograde lymphatic Permeation

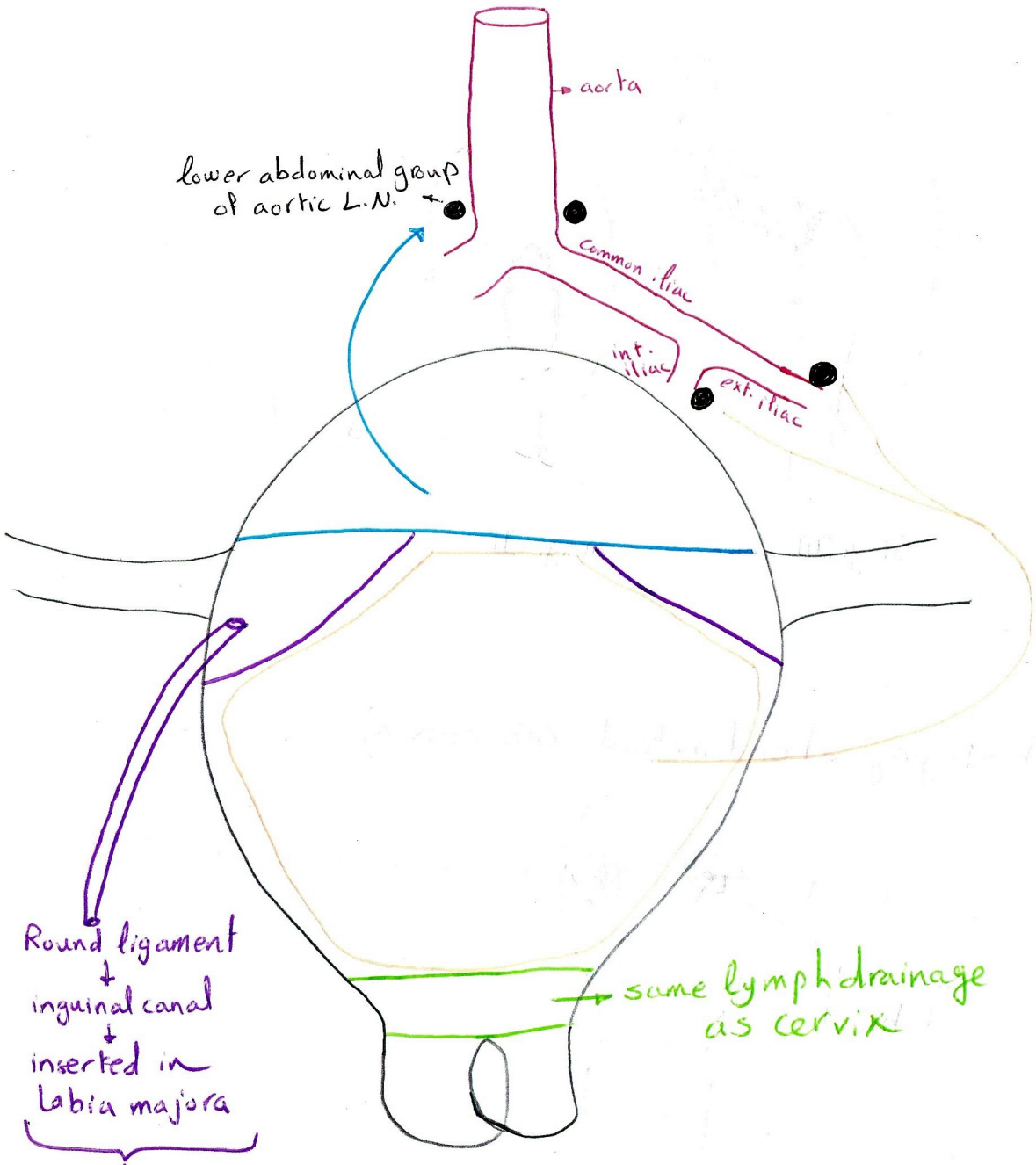

lymphatic spread.

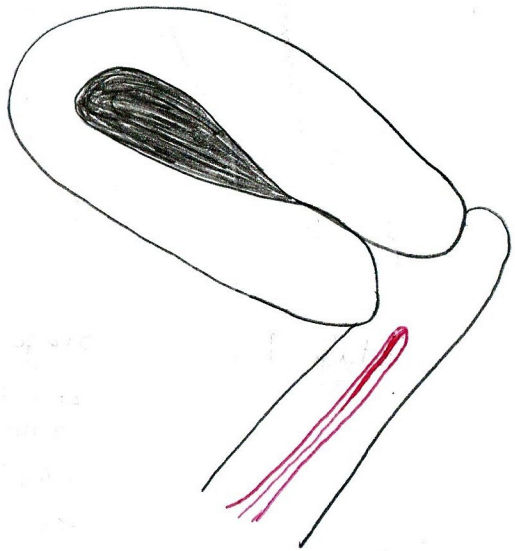

vaginal sonography

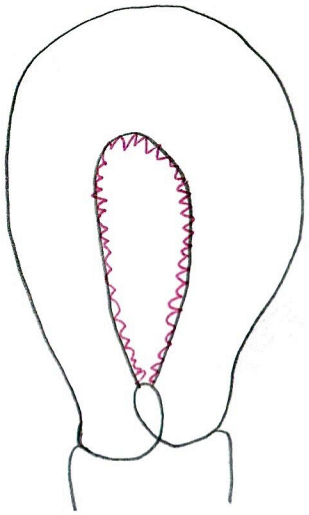

stage I a

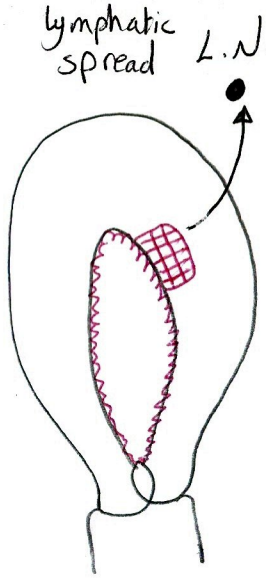

Stage I b or C

"once tumour invade myometrium → lymphatic → spread occurs".



Stage III

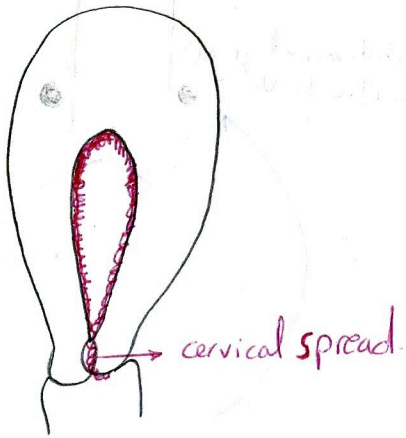

Stage II

(Surgical staging of endometrial carcinoma)

Sarcoma from endometrial stroma

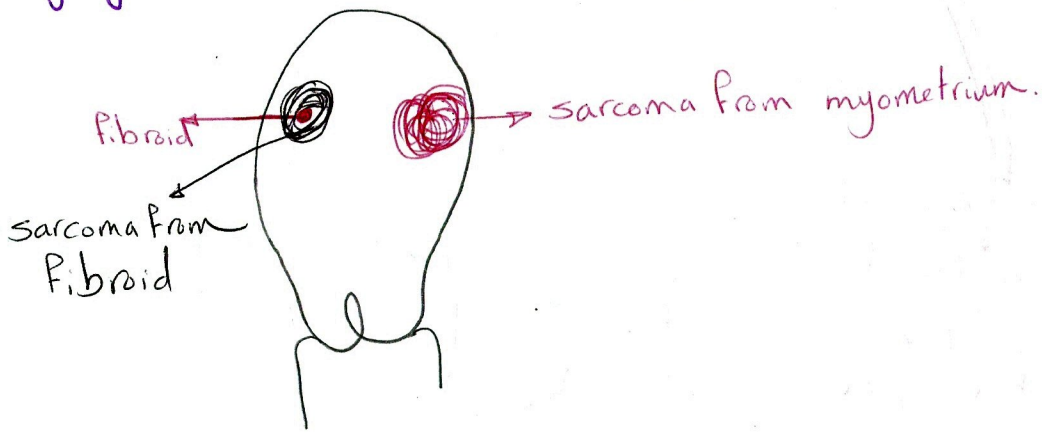

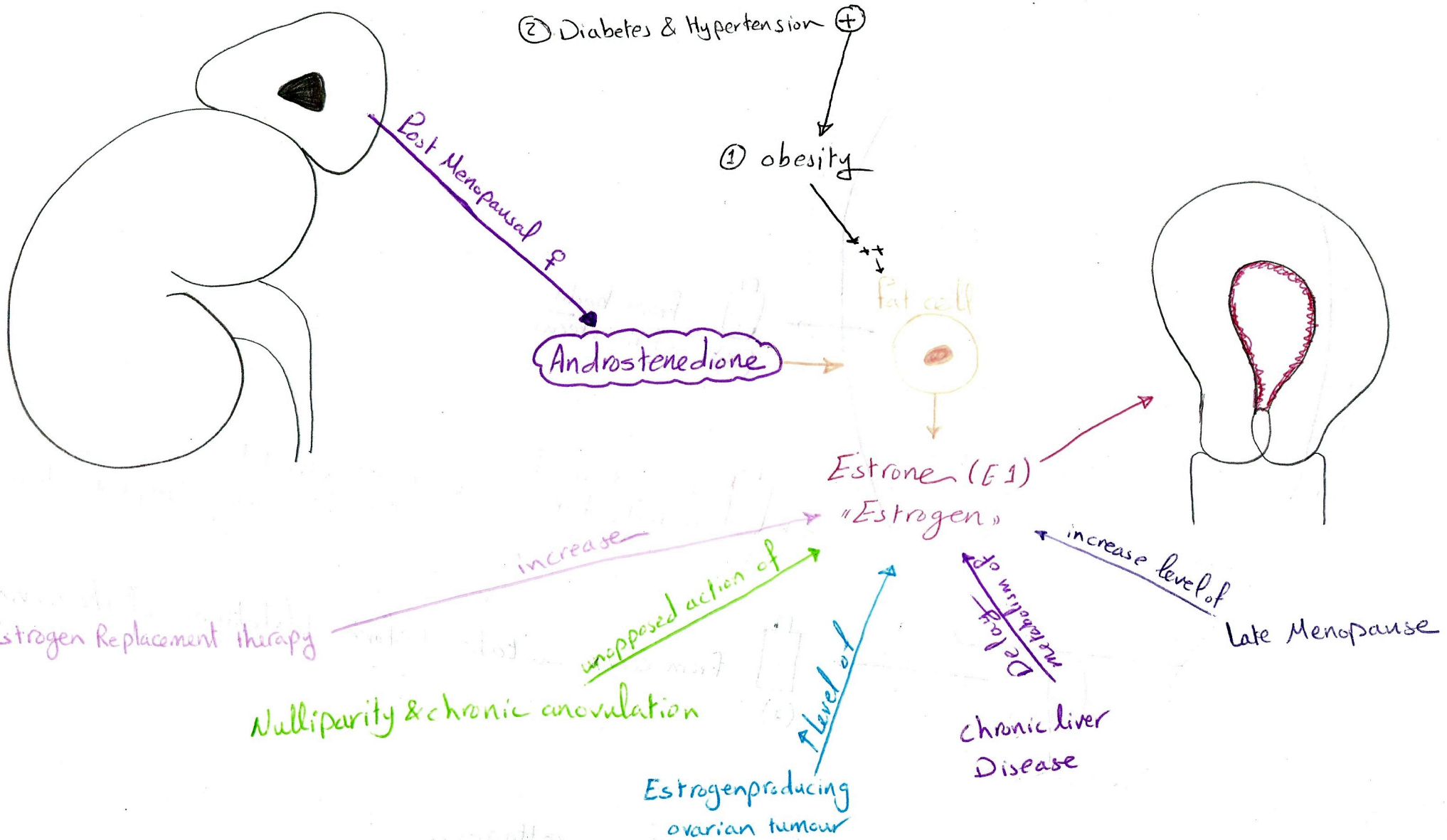

Risk Factors of endometrial carcinoma.

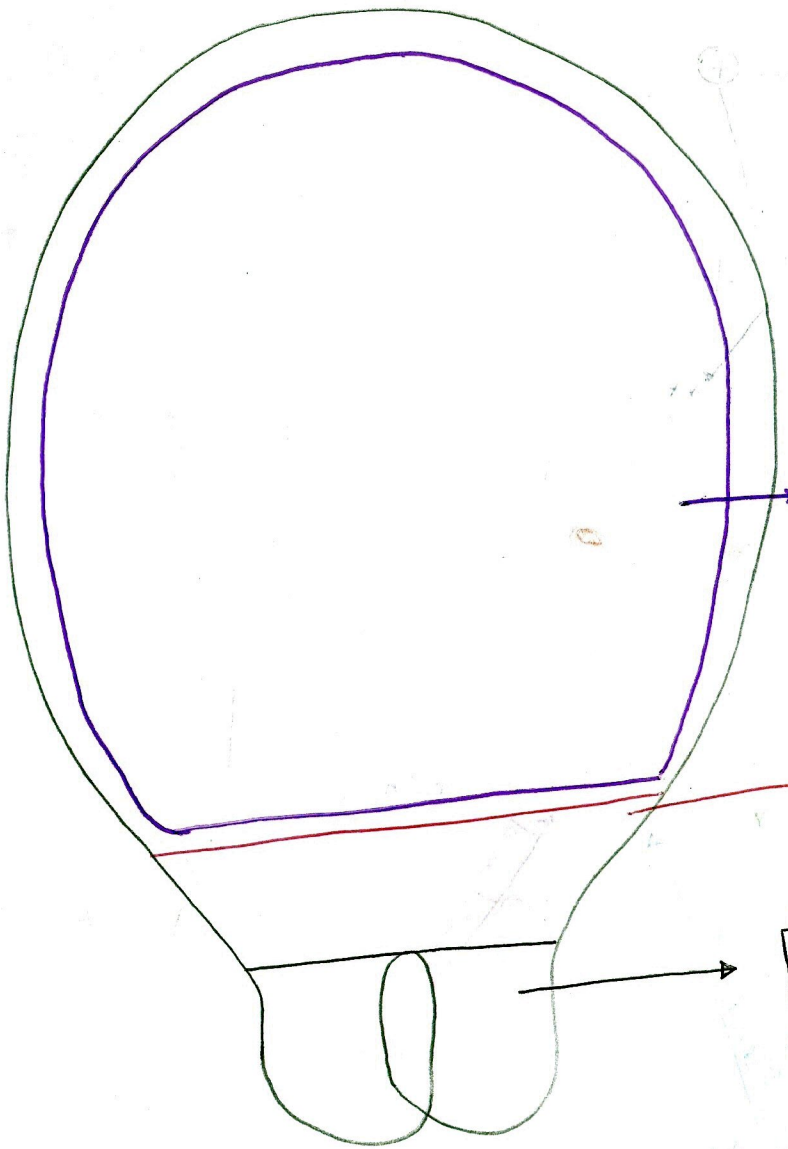

(3) From body of the uterus

(2) lower 1 cm of the body of the uterus → if +ve → treated as cancer cervix as it has the same lymphatic drainage.

(1) From cervix → taken before dilatation of the cervix.

Fractional Curettage.

The story starts Here

↑ Est. in the 1st. day of the cycle → +ve Feedback → Hypothalamus

Receptors which act as sensor for level of sex steroid Hormons (Est. & progest.).

Hypothalamo-Hypophyseal-Portal tract → GnRH → Post. pituitry → Basophils (stores of FSH & LH).

Ant. pituitry

-ve Feedback on ant. pit. to ↓ FSH secretion.

+ve Feedback to secrete GnRH by different pulse

FSH & LH

1st. Half of the cycle more FSH & lower LH

2nd. Half of the cycle (LH surge) & lower FSH.

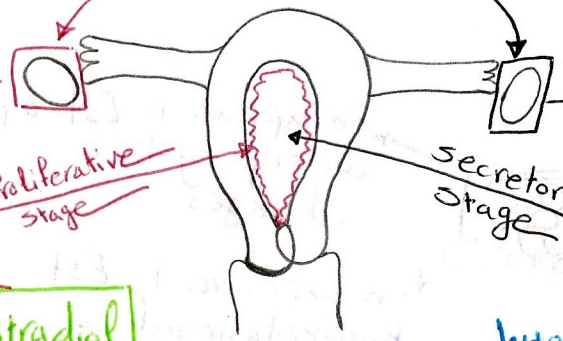

Est. Proliferative stage

Secretory stage

Progest.

LH surge & FSH

FSH & LH

avascular flat granulosa cells

vascular theca interna cells

Primordial follicle

FSH

aromatase

Estradiol & Inhibin

androstenedione

LH

luteinized granulosa cells

LH surge + FSH + Progest.

22 mm

Mature Graafian Follicles

ovulation

ovulation

fluid → absorbed in peritoneal cavity

ovum

corpus luteum (maintained by LH)

No pregnancy

High levels of Est. & progest. → -ve feedback on hypothalamus → ↓ FSH & ↓ LH → Corpus Hrs → Menses

Pregnancy

Fertilized ovum → hCG → LH Like action → Rescue corpus luteum.

* Flat granulosa cells don't synthesize androstenedione as they're avascular.

* Theca interna cells don't convert Androstenedion into estradiol as they don't have the enzyme system (aromatase).



cyclic changes in the ovary

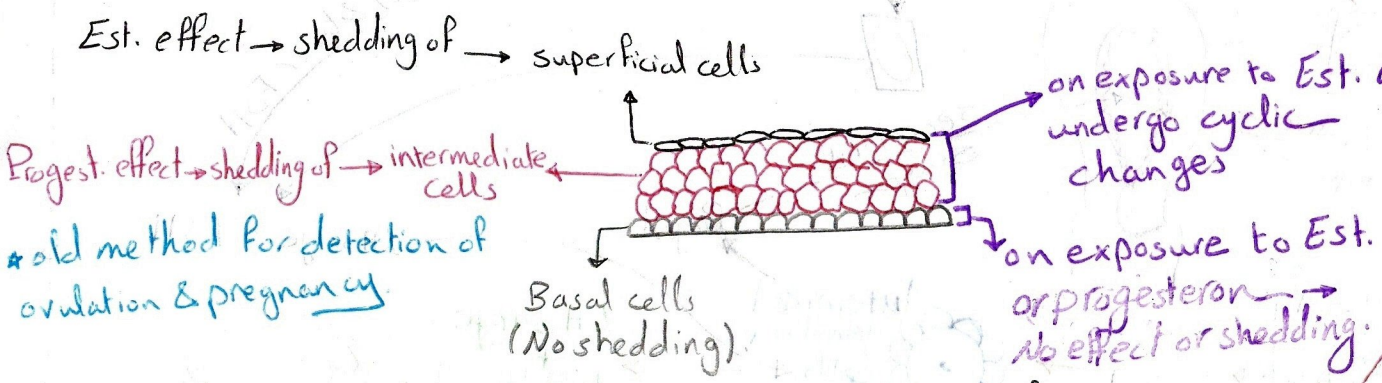

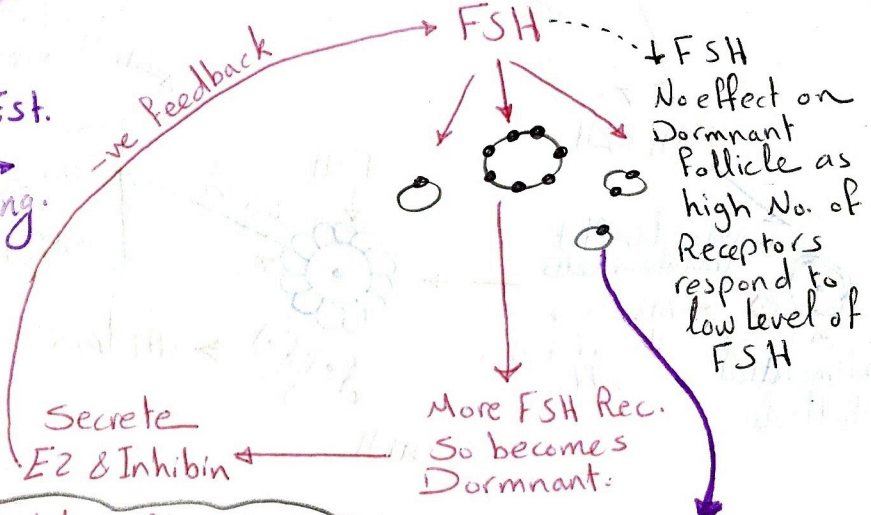

Hints

1- Day 1 is the 1st. day in progest. withdrawal bleeding.

2- Hypothalamus is programmed → when the level of Est. reaches certain level → it recognises that follicle is mature → ↑pituitry for ↗LH surge → ovulation.

3- Progest. production precedes ovulation.

4- ↗LH surge → ↗LH in urine → by its detection we can know that ovulation will occur in next 12-24 hrs.

5- Est. + Progest. pills → maintain level of Hormones in Bl. → No withdrawal bleeding (حبوب الحج والعمرة)

6- Est. + Progest. pills → steady level of Hrs. in Bl. → -ve feedback on hypothalamus → No release of GnRH → No FSH or LH (حبوب منع الحمل)

7- contraceptive pills are taken for 21 days then stopped to allow menstruation.

8- hCG can be detected in Bl. before time of menstruation by 1 week & in urine after time of menstruation by 2days.

9- PGs are secreted from degenerated secretory endometrium only so with chronic anovulation Est. takes the upper hand → only proliferative endometrium → irregular Est. withdrawal bleeding which is continuous & painless.

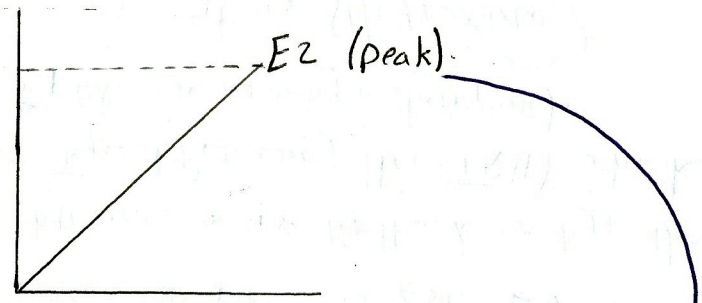

+ve feedback on hypothalamus

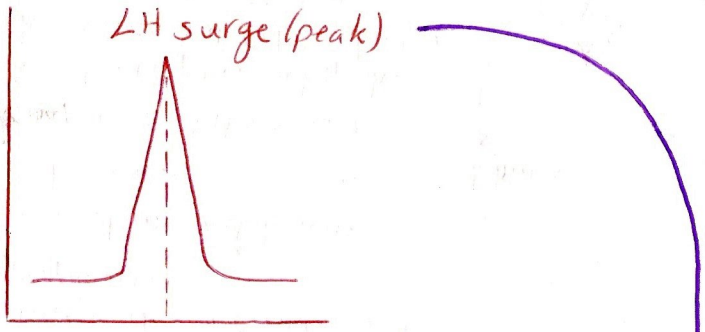

luteinization of the follicle

Progesterone

↓UF

No ovulation

ovulation

ovum

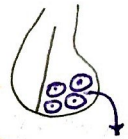

Decrease Prolactin (3)

FSH & LH

(2) ↓FSH

(1) ↓ function of corpus luteum

Progesterone

(5) ↓ progesterone

* if ♀ is pregnant give Her Progesterone in 1st. period of pregnancy.

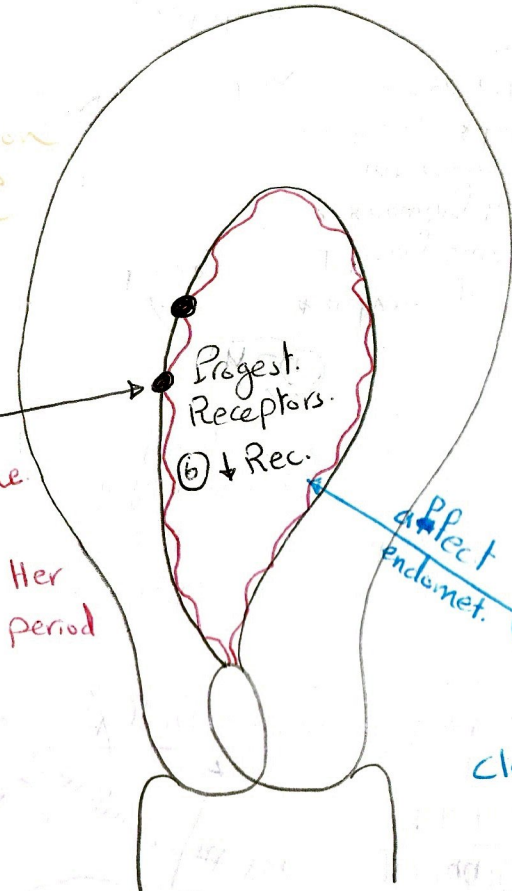

(4) Drugs

↓

progestine

Clomiphene Citrate

Causes of Luteal phase defect

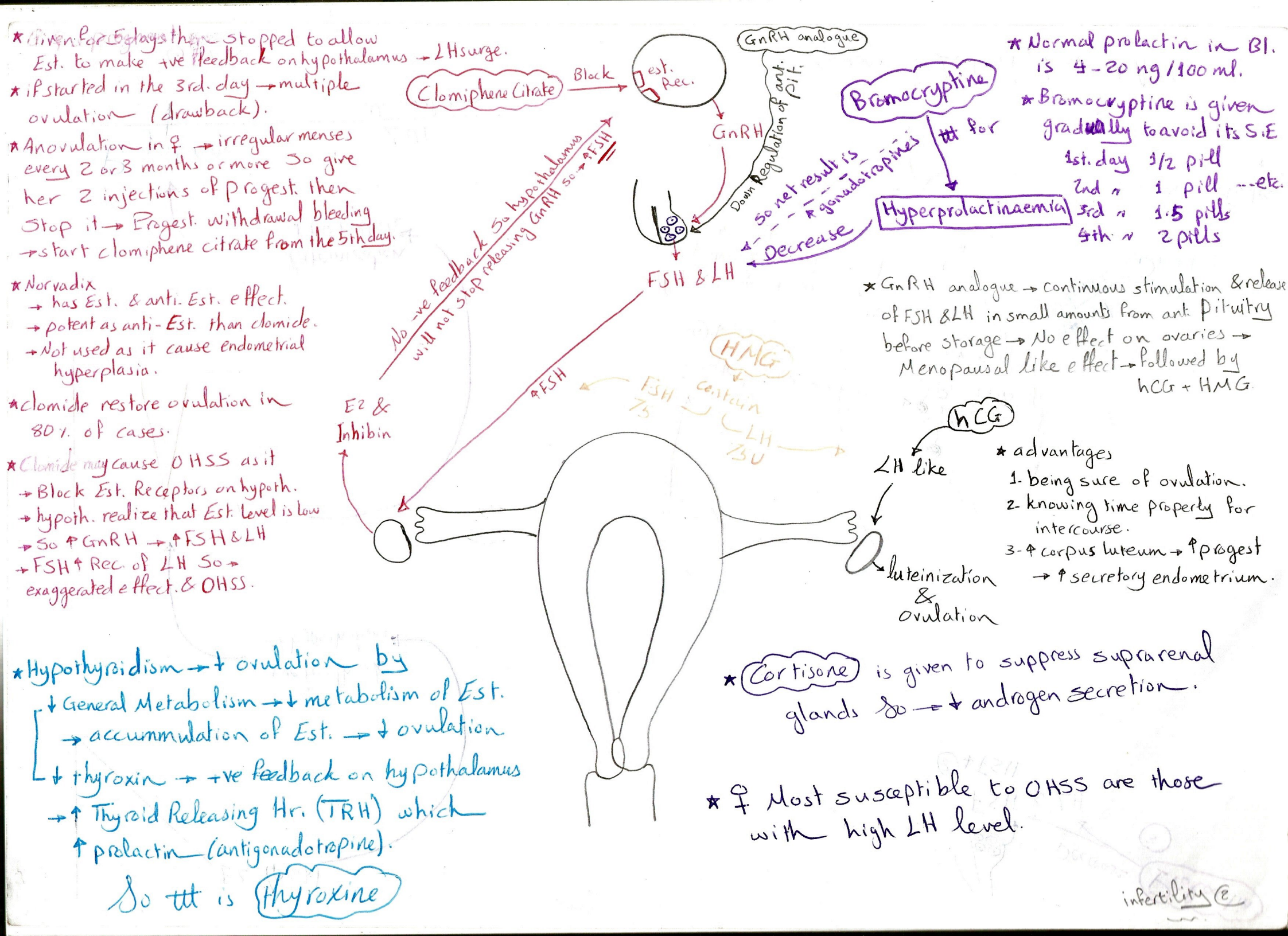

* Given for 5 days then stopped to allow Est. to make +ve feedback on hypothalamus → LH surge.
* if started in the 3rd. day → multiple ovulation (drawback).
* Anovulation in ♀ → irregular menses every 2 or 3 months or more So give her 2 injections of progest. then Stop it → Progest. withdrawal bleeding → start clomiphene citrate from the 5th day.
* Norvadix
  → has Est. & anti. Est. effect.
  → potent as anti-Est. than clomide.
  → Not used as it cause endometrial hyperplasia.
* clomide restore ovulation in 80% of cases.
* Clomide may cause OHSS as it
  → Block Est. Receptors on hypoth.
  → hypoth. realize that Est. level is low
  → So ↑ GnRH → ↑ FSH & LH
  → FSH ↑ Rec. of LH So → exaggerated effect. & OHSS.

* Normal prolactin in Bl. is 4-20 ng/100 ml.
* Bromocryptine is given gradually to avoid its S.E
  1st. day 1/2 pill
  2nd " 1 pill ...etc.
  3rd " 1.5 pills
  4th " 2 pills

* GnRH analogue → continuous stimulation & release of FSH & LH in small amounts from ant. Pituitry before storage → No effect on ovaries → Menopausal like effect → followed by hCG + HMG.

* advantages
  1. being sure of ovulation.
  2. knowing time properly for intercourse.
  3. ↑ corpus luteum → ↑ progest → ↑ secretory endometrium.

* Hypothyroidism → ↓ ovulation by
  ↓ General Metabolism → ↓ metabolism of Est.
  → accummulation of Est. → ↓ ovulation
  ↓ thyroxin → +ve feedback on hypothalamus
  → ↑ Thyroid Releasing Hr. (TRH) which ↑ prolactin (antigonadotropine).

So ttt is thyroxine

* Cortisone is given to suppress suprarenal glands So → ↓ androgen secretion.

* ♀ Most susceptible to OHSS are those with high LH level.



oedema → ↑ size of the cells.
exudate → fibrin → adhesions.



Trendelenburg position
"to move intestine away from uterus".

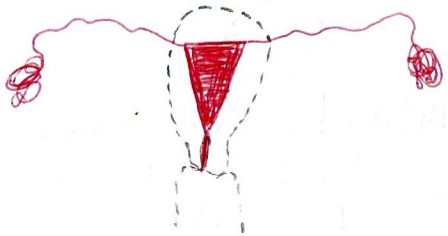

Normal patent tubes

filling Defect
e.g. sub-mucus myoma

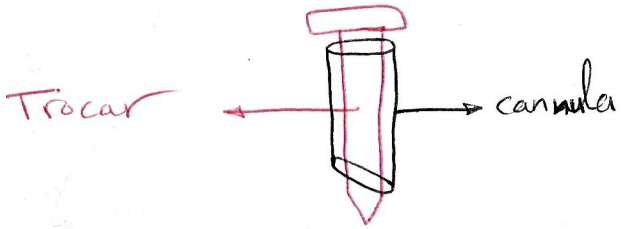

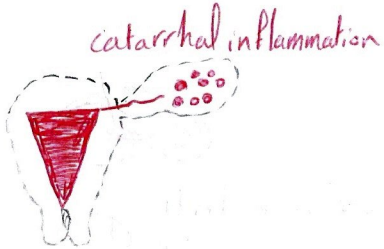

Hydrosalpinx

Dilated lymph vs.



dwarf uterus
due to fibrosis → ↓ size

T.B.

★Doctors of anaesthesia don't like laparoscopy due to:

1- CO_2 effect on heart → arrhythmia.
2- Position → limited movement of the diaphragm.
3- prolonged time of the operation.

★laparoscopy is contraindicated in:-

[Peritonitis
previous pelvic operations] } adhesions so you may injure intestine or ---- etc.

★ Cyclic Progesterone is given at the 16th day of the cycle & continued for 15 days then stopped → progest. withdrawal bleeding & this ttt is continued for 6 months then assess → symptoms & investigations as patient may recover when weight loss occur or with metformin.
→ if no recovery repeat progest. for another 6 months.
→ if ♀ will marry we'll give Her clomidine for induction of ovulation.

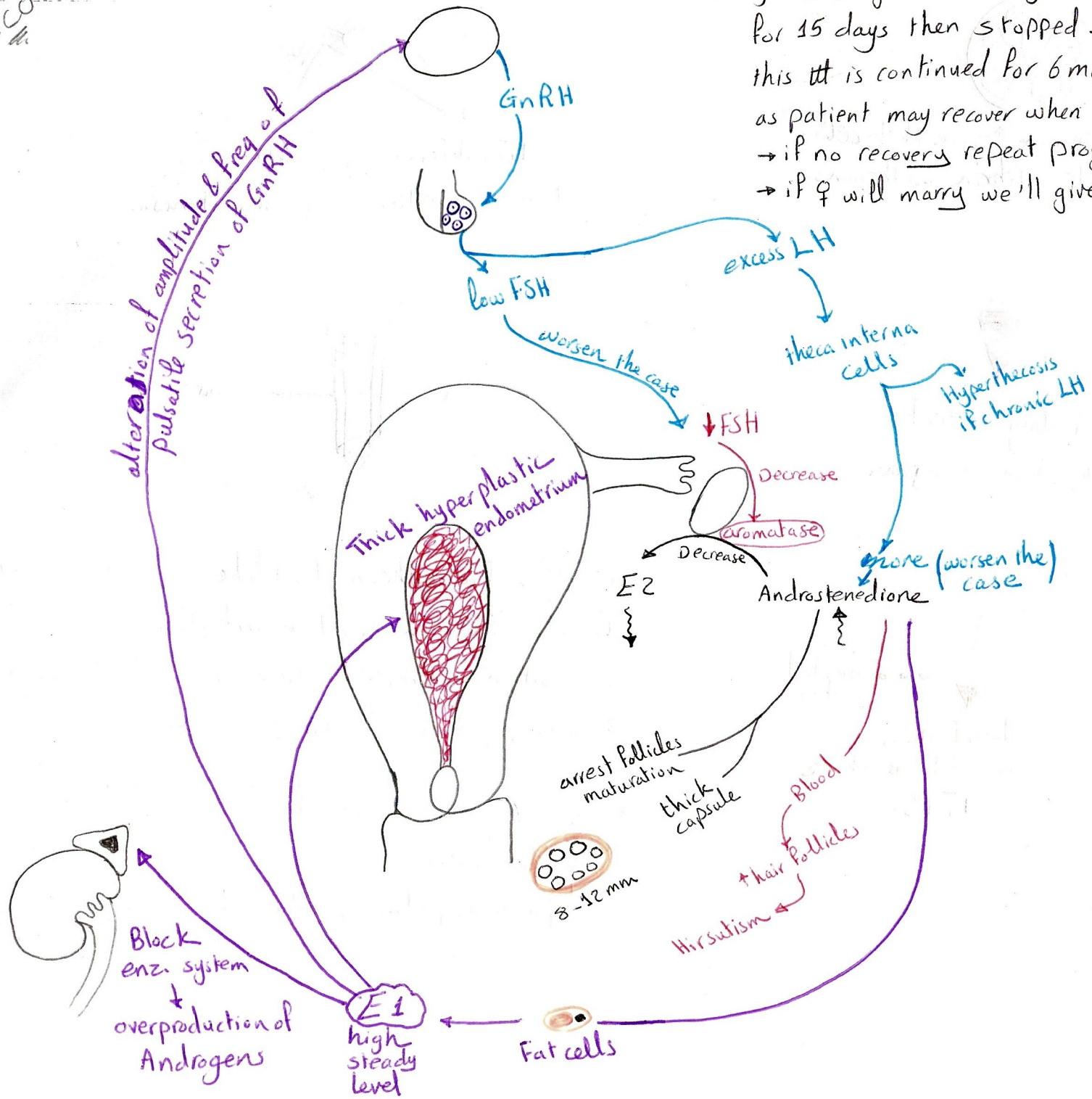



Bilateral wedge resection

★ Was used in 1935 & show success of ovulation for 5 months or more (enough for pregnancy) due to trauma of the ovary but after 5 months will be so bad than before as suture material in the past was bad → pelvic adhesions

ovarian drilling (ثقب المبايض)

★ Recently using laparoscopy we introduce a probe & induce cauterization of theca interna cells

★ Ovarian Decortication تقشير المبايض may be used if the ovarian capsule was thick enough to prevent ovulation.

Normal flow → then → spotting

Corpus luteum is resistant to degeneration (slow degeneration)

↓ progesterone slowly

all endomet. fall except some foci which can resist & not shed with low progest → so make spotting

Delayed shedding of endometrium

LUF	Follicular Cyst
luteinized follicle	Non-luteinized
secrete Est. & Progest.	No Hormonal Secretion
Regular Cycles	Irregular Cycles

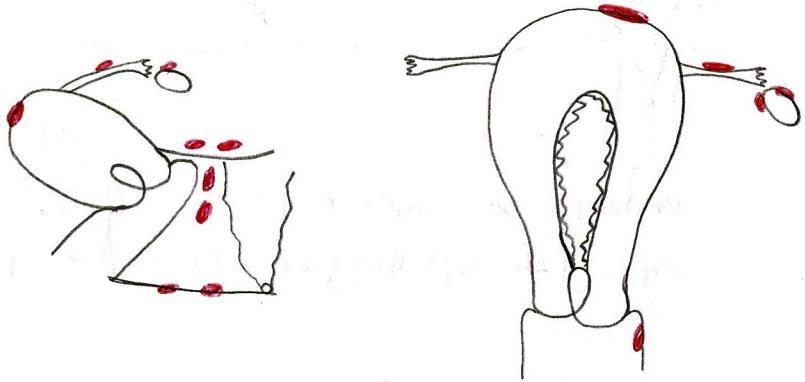

Sites of Ectopic Foci

★ Ectopic endometrial foci either have Normal Hormonal Response or abnormal hormonal response to Est. & progest. so some cases respond to Est. stimulation by secretory endometrium.

★ Dysmenorrhea is either
- Congestive (Heaviness) قبل نزول الدورة
- Spasmodic أثناء نزول الدورة

Both types are present with endometriosis due to ↑ tension in small cysts.

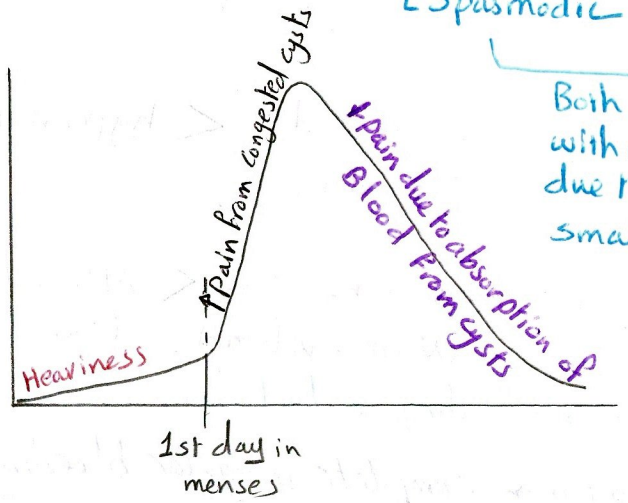

Crecendo Pattern

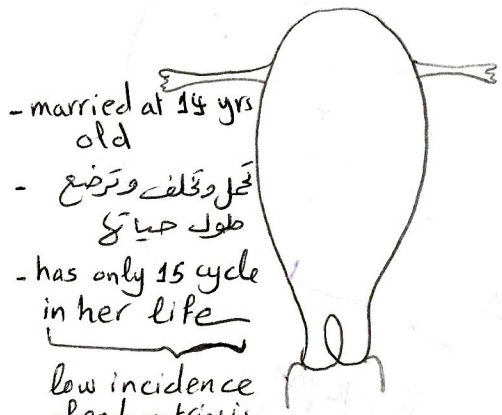

- married at 14 yrs old
- تحمل وتخلف وترضع طول حياتها
- has only 15 cycle in her life

low incidence of endometriosis

الفلاحة

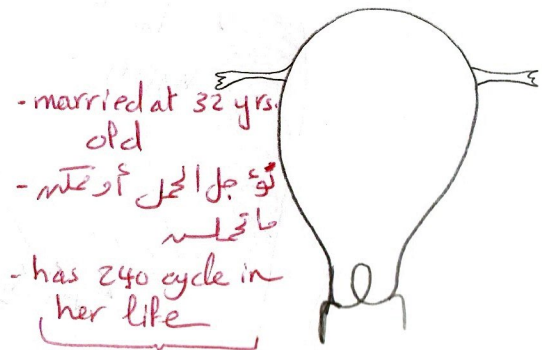

- married at 32 yrs. old
- تؤجل الحمل أو تتعلم ما تحلب
- has 240 cycle in her life

high incidence of endometriosis

المتعلمة

★ Endometriosis is common in highly educated & high Social level ♀.

Polymenorrhea < 3 weeks → 4 → 5 weeks < oligomenorrhea
(Normal cycle)

Hypomenorrhea < 2 → 7 day < hypermenorrhea
(Normal bleeding)

قلة ← 30 → 80 cc < Menorrhagia (excessive bleeding)
(Normal volume)

* Metrorrhagia → bleeding in between cycles.
* Menometrorrhagia → complete irregular bleeding.

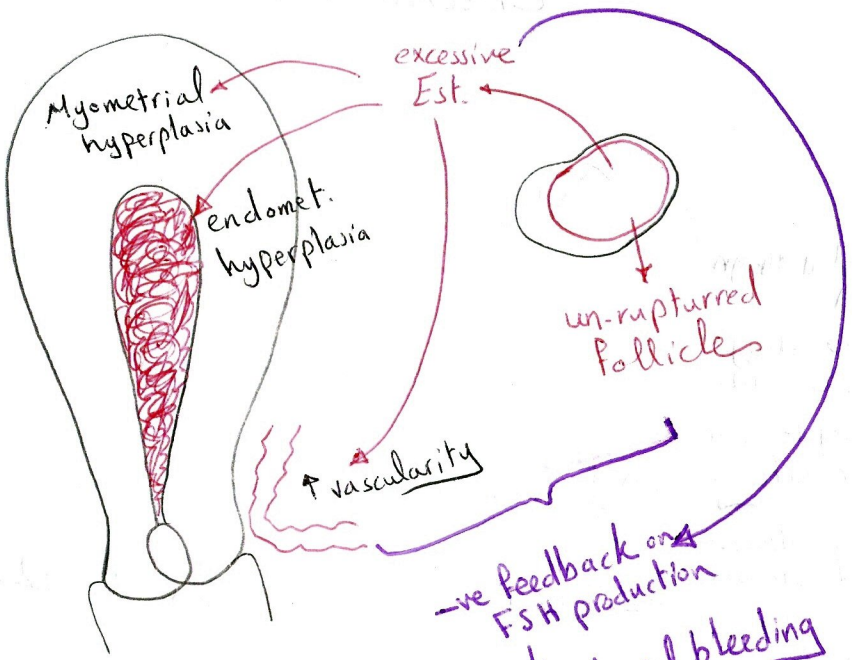

-ve feedback on FSH production
↓
Est. withdrawal bleeding
excessive [↑ thickness of endomet.
↑ vascularity
No PGs from proliferative endomet.
Painless → No uterine cont. (No PGs).

Metropathia Haemorrhagica

No ovulation as No high steady level of Est. that can cause +ve feedback on hypothalamus & Release LH surge.



Threshold bleeding.

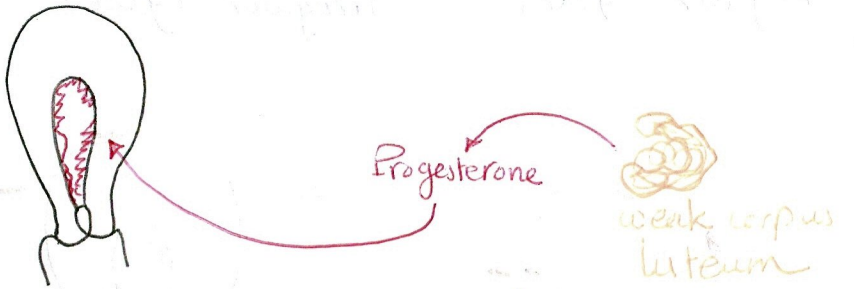

endometrium don't respond to progesterone equally so spotting occurs before proper flow.

Dysfunctional Menorrhagia



withdrawal inclusion Cysts.

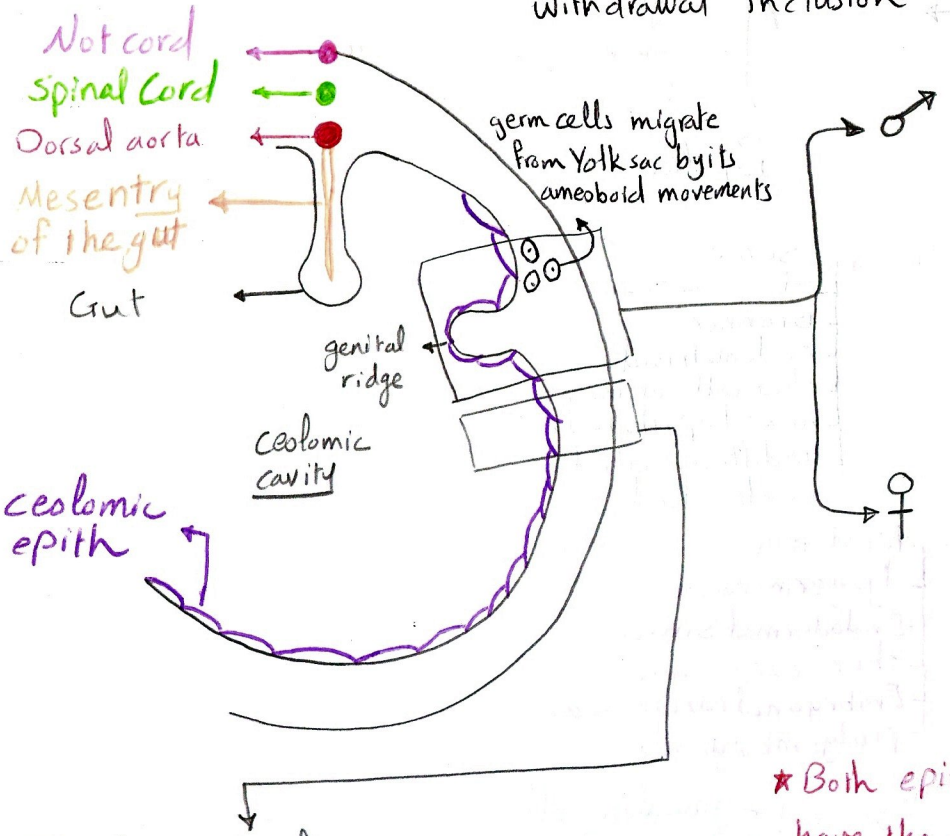

Development of uterus

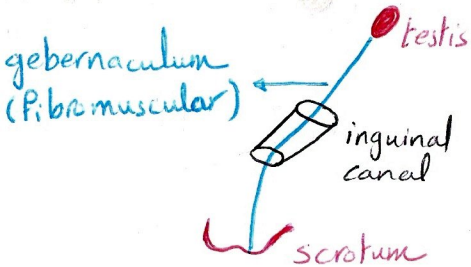

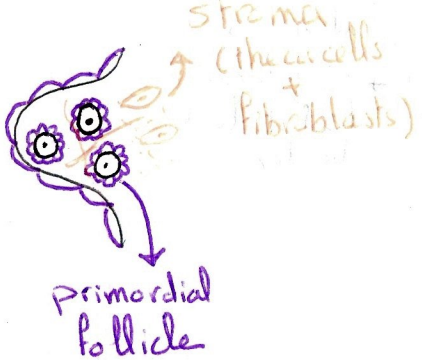

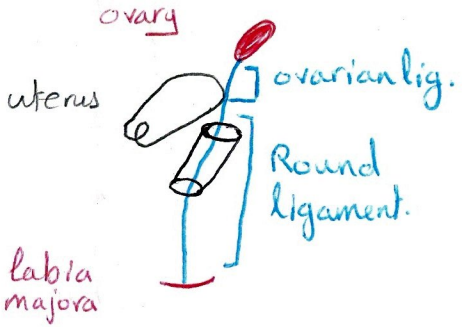

★ Both epithelial cells of the ovary & endometrium have the same origin from coelomic epith. So some of epith. cells of the ovary tumours are of the same pathology like endometrium.

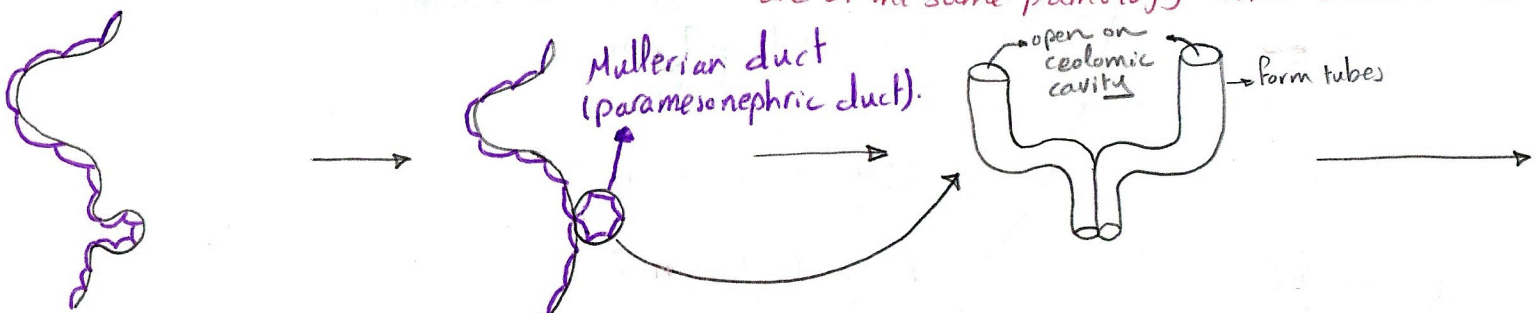

invagination of coelomic epith.

formation of Mullerian duct

Fusion

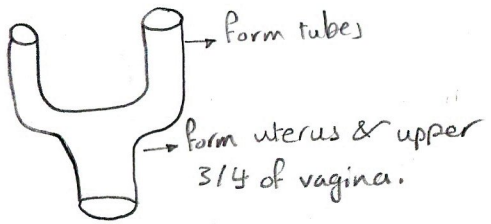

canalization

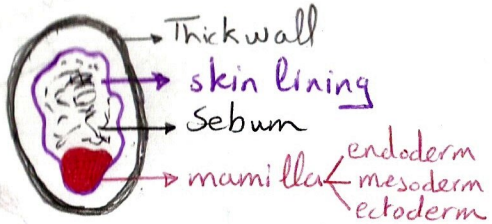

Dermoid Cyst.

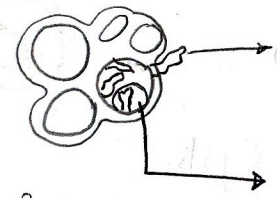

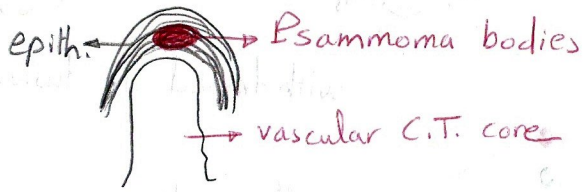

Papilla





Barium enema

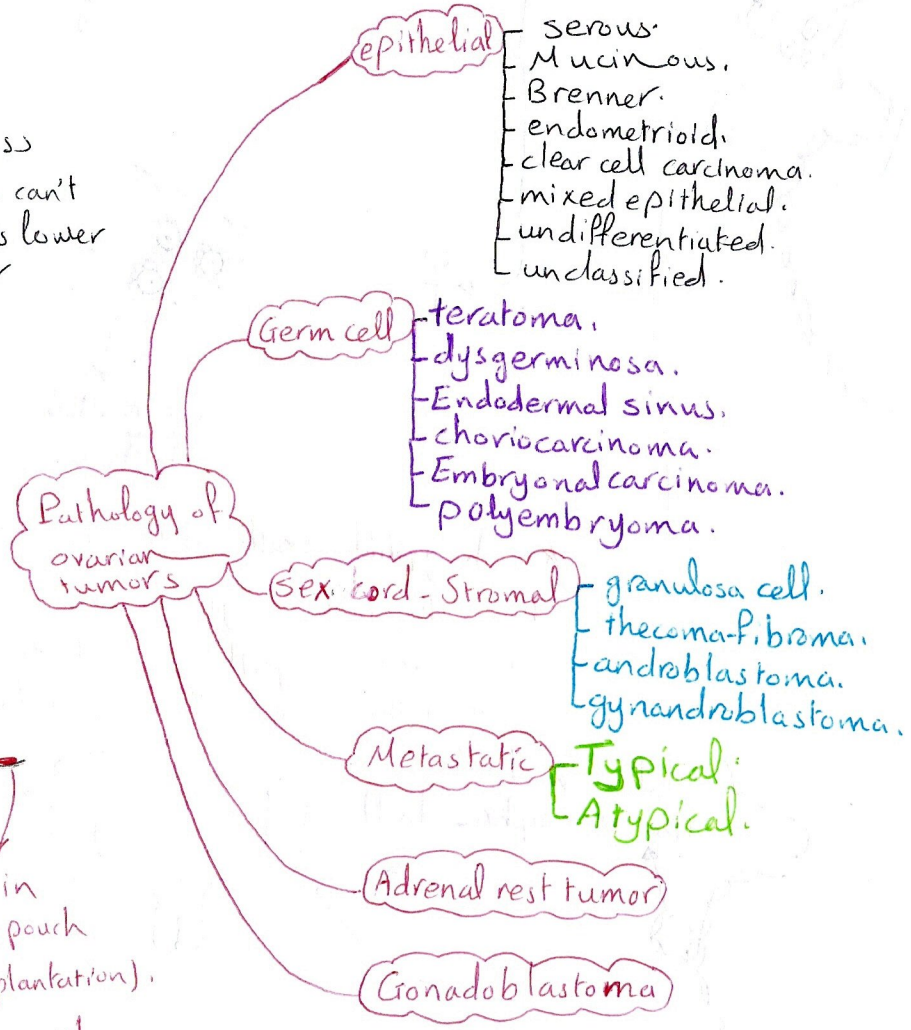

[1] Torsion :-



ovarian tumors

Pulsation of Bl. vs. make ahemodynamic state → ↑↑ torsion.

sudden movements or Peristalsis

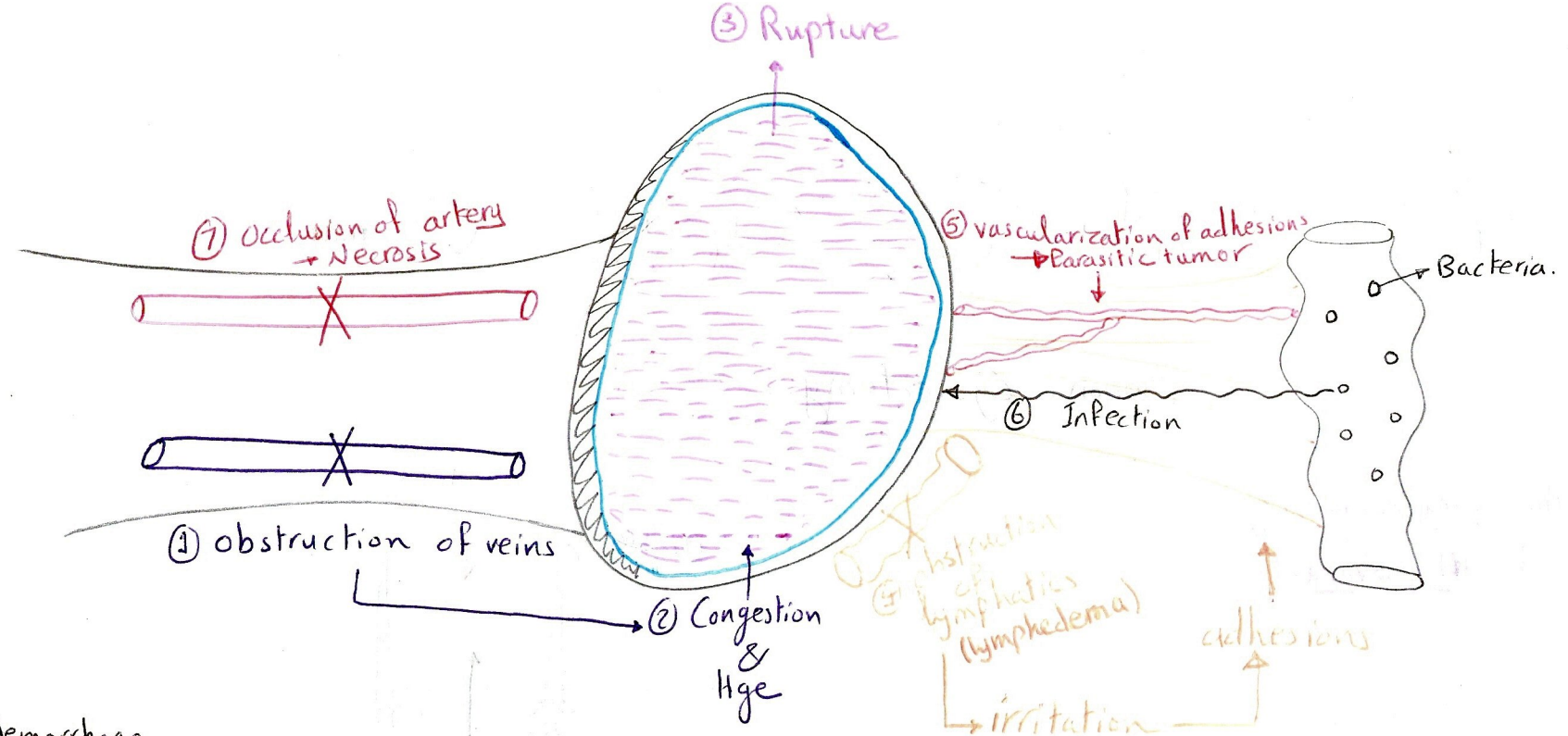

[2] Hemorrhage.

[3] Rupture.

[4] Malignancy.

[5] Impaction. →

} Pelvic pr. symptoms
- pelvic heaviness
- frequency of micturation (compression on urinary bladder).
- difficult micturation (compression on urethra).
- ↑ vaginal discharge (~ ~ veins).

[6] Intestinal obst.

[7] Complication during pregnancy, labor, & puerperium.

[8] Infection:

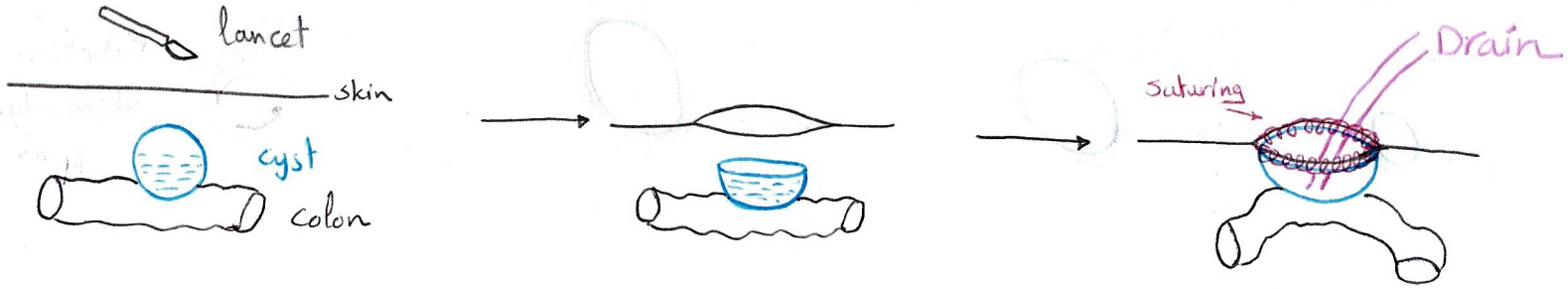

Marsupialization.



Ovarian Cystectomy

* ovariotomy: Removal of the ovary containg cyst.
* ovariectomy: Removal of healthy ovary.

* 3 ligaments are clamped during removal of the ovary:
1. Ovarian ligament.
2- Mesovarium.
3- Infandibulopelvic ligament.

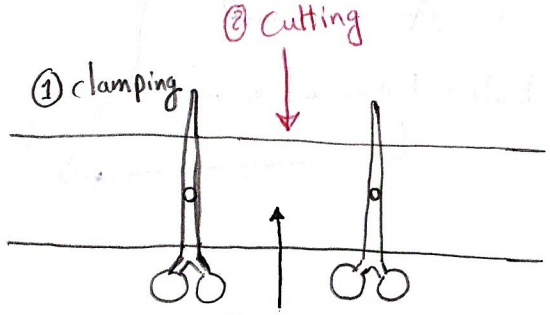

suture should be taken within the substance of the pedicle not only around the surface to prevent spilling of the suture.

Remnants of wolffian duct
↓
cystic dilatation
↓
Paraovarian cyst
↓
stretch of fallopian tubes → closure

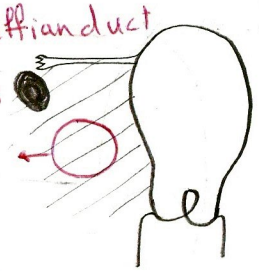

Uterus
- ↑ vascularity
- ↑ size
- cavity → distorted & stretched
- ↑ surface area of endomet.

Fibroid (1)

Kidney
↓
Hydronephrosis

Broad lig. Fibroid
↓
stretch tube
↓
closure

Cornual Fibroid
↓
close tubes

chronic salpingitis

low Bl. supply
↓
Necrosis
↓
infection

Functional cyst
Commonly
Follicular cyst
(just association).

Ureter → hydroureter

calcification → egg-shell appearance.

★ center (low Bl. supply

hyaline degeneration

liquefaction

cystic degeneration

Necrosis

lipoid toxin

thrombosis

intravascular hemolysis → Hb → Hemosidren
↓
Red staining of the tumor.

★ Pregnancy → ↑ Fibrinogen, Bl. stasis → thrombosis

Bl. supply

U.B. → Frequent Micturation

Urethra → urin retention

Fibroid (2)

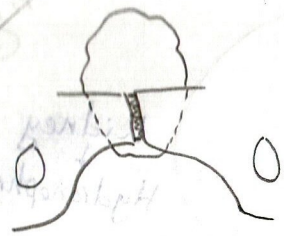

Pelvi-abdominal

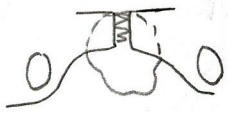

Pelvic

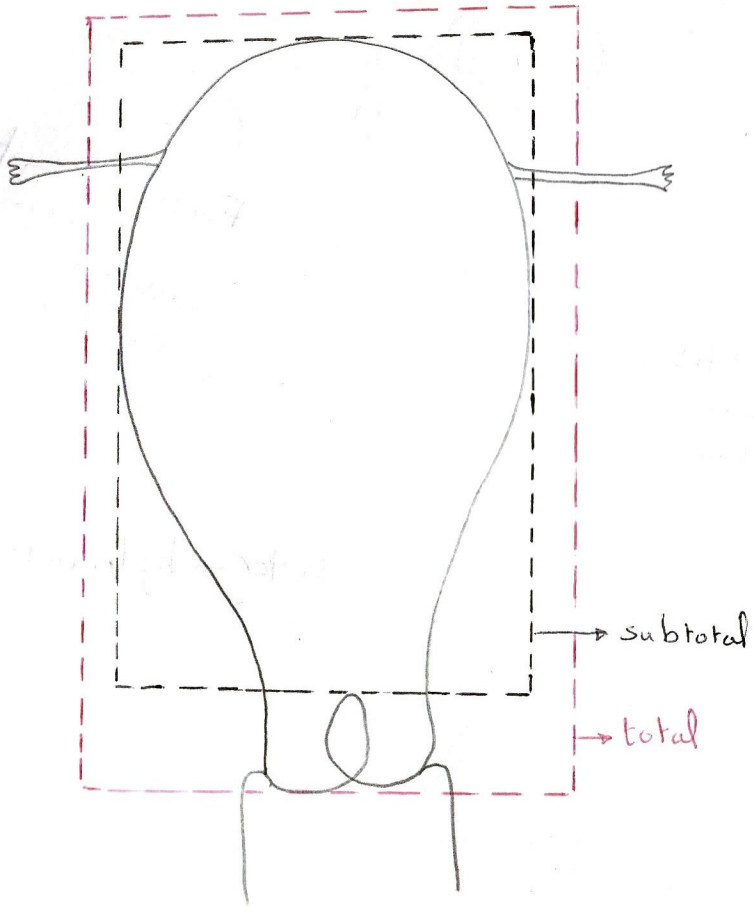

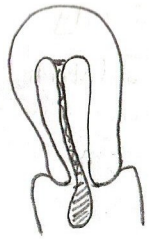

Submucous fibroid Polyp

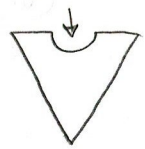

filling defect (submucous fibroid).

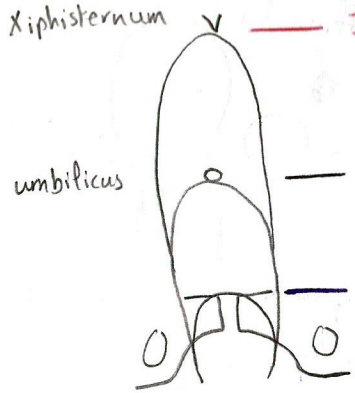

*In 1940 Doctors tended to do subtotal Hysterectomy as they thought that:
1. Leaving cx. will make them avoid ureteric or U.B. injury.
2. Cx is attached to transverse ligament → vaginal support.
3. cervical mucous cause lubrication of vagina during the intercourse.

⇒ But some cases developed Cervical stump carcinoma. So →

*Doctors tended to do total Hysterectomy as they suggested that:
1- Removing Cervix will make us avoid cancer in cervical stump.
2- Cervical mucous is not lubricant for vagina.
3- Cervix weight cause prolapse of vagina.

⇒ But in 1970 & 1990 they returned to subtotal Hysterectomy as they found that:
1. Cervix has important role during intercourse.
2. Survey of ♀ by pap smear + incidence of cervical stump carcinoma as if you find dysplastic cells you'll do conization & no fear of malignancy transformation which takes place in 10 yrs.

Unilateral Salpingo-oophorectomy may be done in some ♀ to avoid sudden extensive menopausal Symptoms.

TAH & BSO = Pan Hysterectomy → حد يكبوا الاكم دي

Radical Hysterectomy: of 5 grades
Grade III → Wertheim's operation.
Grade I → Pelvic excentration.

Myomectomy

Fibroid ③

[1] Preoperative preparations.

[2] Incision.

[3] Hemostasis.

- Rubber tourniquet

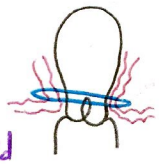

removed every 1/2 Hr. not to allow Bl. supply to uterus as it's supplied by ovarian artery & other anastomosis but to avoid:-

a. sever Hypotension:- if the tourniquet applied for along period when it's removed → sever hypotension so anaesthesia doctor should inject saline when you try to remove the tourniquet.

b. Shock from accummulated Histamine.

[4] Removal of the fibroid:-

- incision in uterus in midline → least vascular area
- On anterior wall not posterior to avoid intestinal adhesion & pelvic adhesions → ↓ fertility.

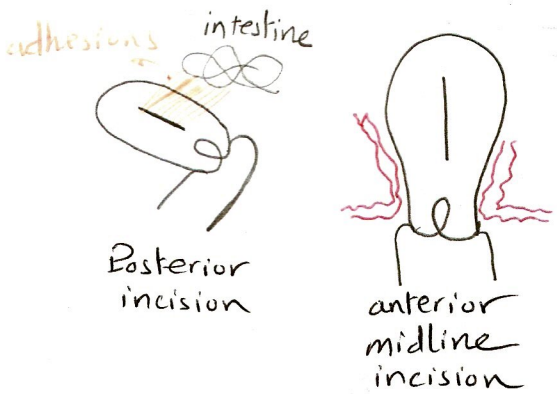

a. if single fibroid (single firm mass in PV).
- incision → retraction of stretched ms.
- enucleation (نقشر الورم زى البرتقال اليوسفى)
- suture the cavity → tumor bed
- trimming
- Reach the cavity to remove any small submucous fibroid (fibroid seeding).

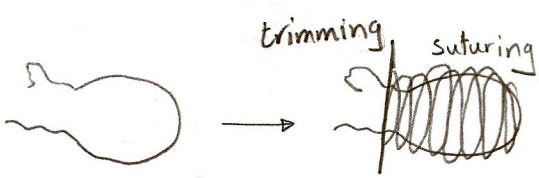

- Before closure ① Do complete hemostasis:-
  Peritoneal lavage بمحلول ملح + Drain + Leaving some saline + Heparin (Heparinized saline) as heparin → ↓ Factor X → ↓ Bl. coagulation so ↓ pelvic adhesions.

② Shorten stretched Round ligament

b. Multiple Myomata:-

planning (suitable plan).

c. Post. wall myoma:-

transcavitary



Bonney's hood operation

d. Subserous myoma

clamping & incision

- to control bleeding we do:- correction of anaemia, timing, GnRH analogues & Petressin.
- to control adhesions → proper hemostasis, ant. wall incision, drain & Plication of Round ligament.

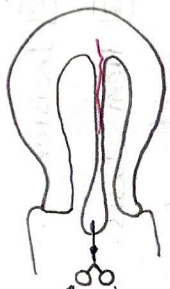

Small & thin polyp twisting & removal.

* after removal of the polyp → Retraction of Bl. vs. in myometrium so we give pitressin to ↑ uterine Contractions.

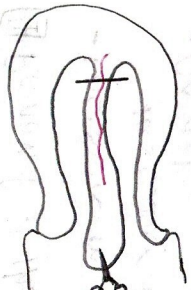

Large & big polyp → cutting near the base of the polyp

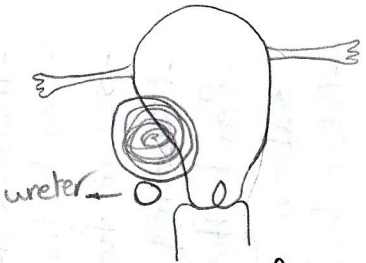

False broad lig. fibroid lateral displacement of the ureter

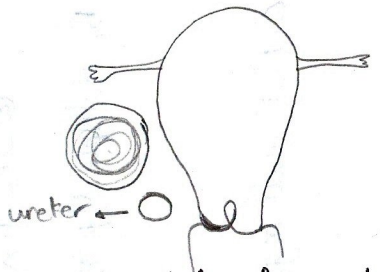

true broad lig. fibroid medial displacement of the ureter



Cervical fibroid polyp

as cervix can't contract.

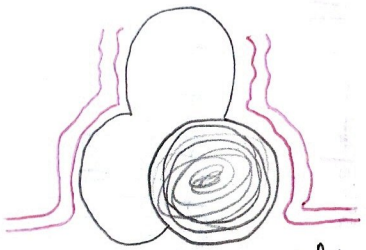

Interstitial cervical fibroid

Myomectomy is difficult to be done due to difficult hemostasis :-

1- tight field so rubber tourniquet is difficulte to be done.
2- fibroid is near the main stem of uterine artery
3- No myometrium to contract & close Bl. vs. of the tumor bed.

⇒ Nowadays :- through uterine cavity we split the fibroid into 2 halfs and scrap the fibroid near to the capsule then suture before injury of capsular Vs.

Respond to Hrs.
↓
Hge on rupture
↓
irritation of uterine wall
↓
Hyperplasia
↓
- symmetrical enlargement (common)
- Asymmetrical ~ if localized bulge

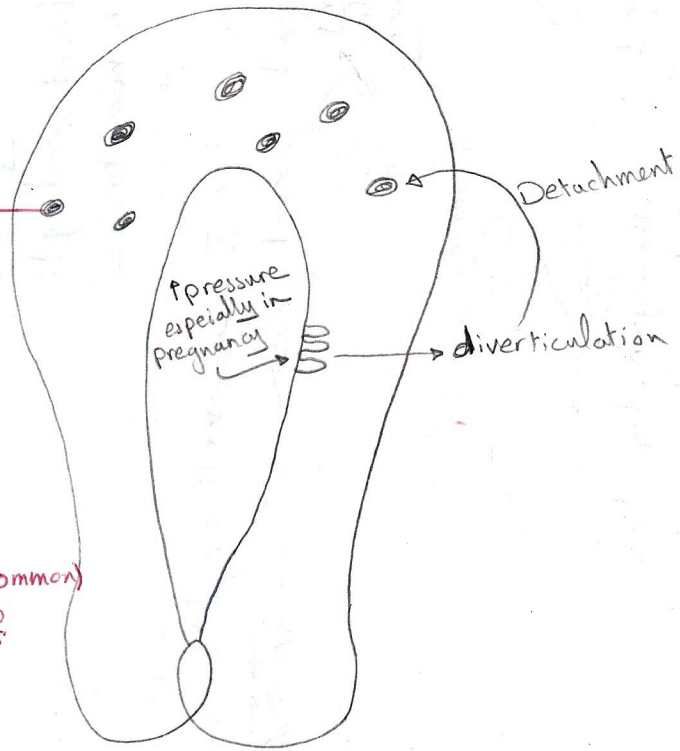

Adenomyosis

Contraception

Combined OCPs
↓
Estrogen + Progestine } high steady level of Hrs.

-ve feedback on hypothalamus

↓GnRH

↓Gonadotropines

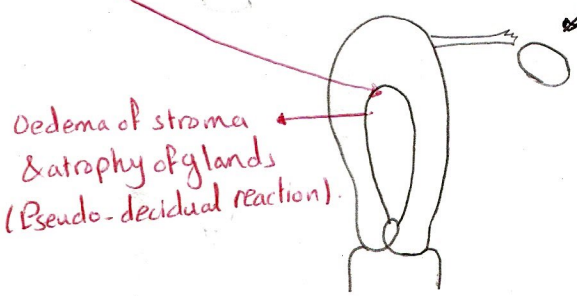

- No ovulation.
- No Hr. production.

Oedema of stroma & atrophy of glands (Pseudo-decidual reaction).

* High est.
  - ↑ coagulability.
  - wheight gain & salt & water retention.
  - Hyperplastic endometrium.
* Progesterone alone:-
  - Bad mood & dizziness
  - Bad lipid profile → ↑LDL → ischaemic Heart disease.

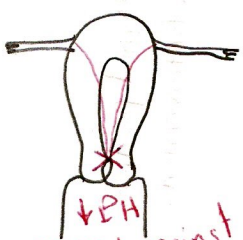

↓PH
protect against ascending salpingitis

← advantage

Estrogen Disturb CHO metabolism
↓
+++ glycogen

Lactate
↓
↑ vaginal acidity
PH = 4

Lacto-bacilli

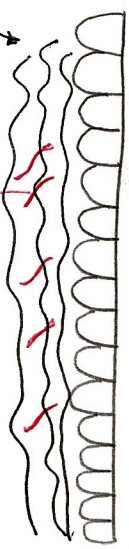

vaginal epith.

← Disadvantages

acidity suppress all commensals & favor monilial infection which is fungal infection causing vaginitis & not ascending infection.

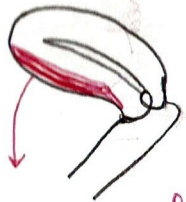

- ↑tone in ms of ant. wall → AVF
- on stretching by volsellum → Retroversion.

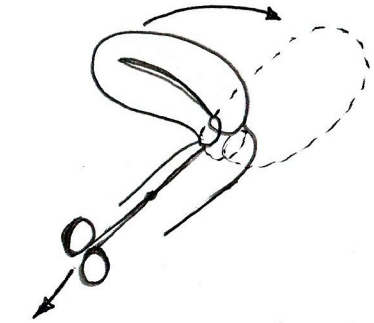

Retroversion.

grasping anterior lip.

this mark
- if looks upward → Normal position.
- if looks downward → Retroversion.

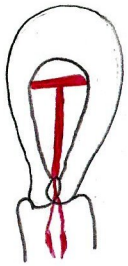

Inserted IUD

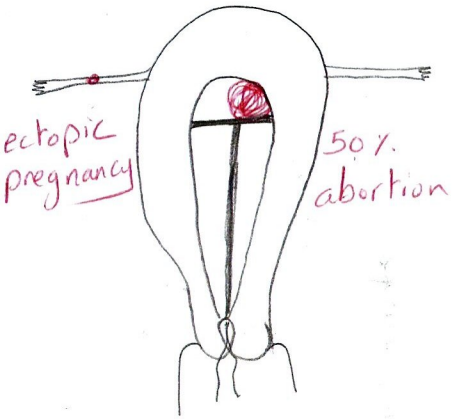

ectopic pregnancy

50% abortion

Rim

Reservoir

Condom



Spermicidal

Diaphragm

Cervical cap used with prolapse

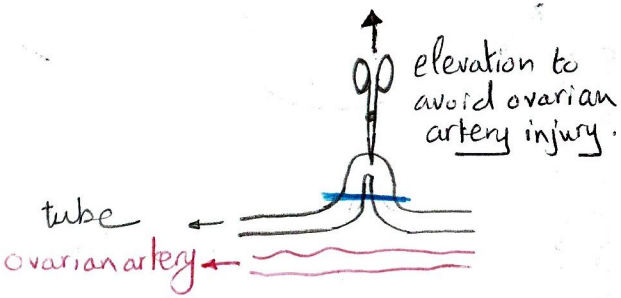

elevation to avoid ovarian artery injury.

tube

ovarian artery

Madlener

fimbrial end

Kroener (Fimbriectomy).

Rest of Phys. changes During Pregnancy

Endocrine changes

[1] Pituitary:

↑ size
↑ activity
Not of Bl. supply } Relative Decrease of Bl. supply

So obstetric bleeding → Bl.vs. make V.C.
→ ischaemia of hypertrophied pituitary
→ ↓PRL → no lactation.
↑ Gonadotropines → No menses } Sheehann's Syndrome.
↑ TSH → Hypothyroidism.
↓ ACTH → Hypocorticalism.

[2] Thyroid. physiological goitre.

[3] Adrenal. ↑ bound cortisol.

[4] Parathyroid. ↑ size & activity.

[5] Placenta. ↑ Hrs. production.

Musculoskeletal System.

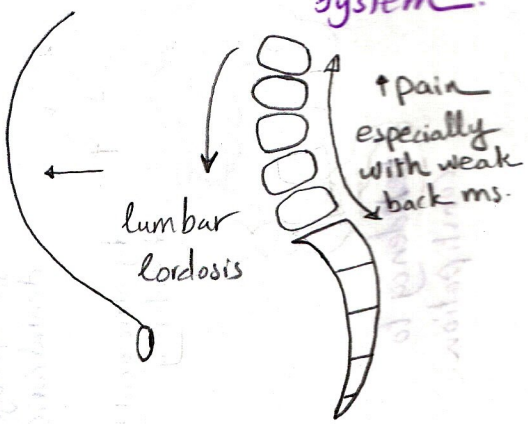

1st day of LMP

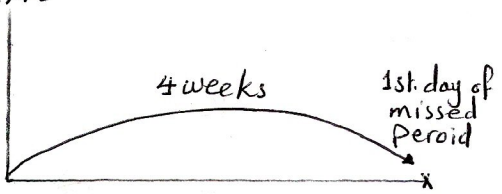



① soft uterus
② empty lower part of uterus till 10 w.

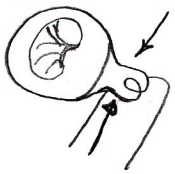

Hegar sign

* not felt in non-pregnant ♀ as uterus is firm

Gestational Sac 4 weeks → one fetal pole 5 weeks → 2 fetal poles 6 weeks → Fetal Heart activity 7 weeks → auscultation by Doptone

Vaginal ultrasonography

Doptone: send ultrasonic waves
→ strike moving obj (fetal heart)
→ return of waves by diff. freq.
→ explained as beats by the operator.

قوانين

[1] EDD (Naegele's formula).

1st day of LMP Date.	1/3/08	8/6/08	27/9/08
	7 9	7 9	7 9
EDD	8/12/08	15/3/09	4/7/09

[2] calculating fetal age:-

Today's date	23/11/08	23/11/08
Date of 1st day of LMP	22/8/08	8/5/08
Fetal Age	1 3	15 6
	(13w) ٣ شهور ويوم	٦ شهور ويوم (28w)

* لازم نقول عمر الجنين بالأسبوع
* كل ٣ شهور تزود أسبوع

(3m = 3×4 +1)
= 12 +1
= 13 weeks

Phys. Changes During Pregnancy

Genital organs

1] Uterus.



size	7.5 cm	35 cm
weight	50 gm	1000 gm
Vascularity	50 ml./min.	900 ml./min.

stretch of Round lig.
↓
Pain in iliac fossa mostly Lt. side due to dextrorotation.

Active segment
Passive segment

Peritoneum attachment

Membranes attachment

2] Cx & vagina.

soft bluish cx. & vagina

3] ovaries.

large CL

Cardio vascular System

1] Bl. volume :-

Lakes of Bl. sinusoids to contain excess Blood. So no ↑ in Bl. pr.

2] Cardiac Output :-

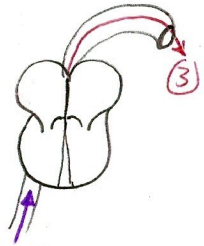

3] Leucocytosis

4] ↑ platelets & fibrinogen.

5] Venous Stasis :-



6] Bl. pr.

1st. trimester	Normal
2nd trimester	↓↓
3rd. trimester	Normal

GIT

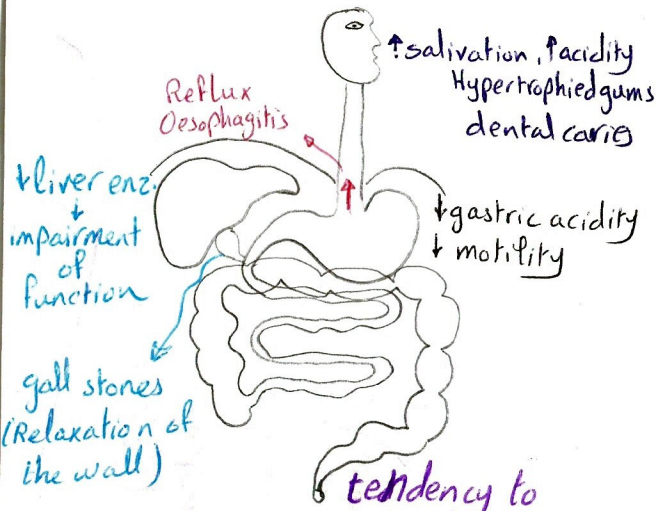

Urinary system

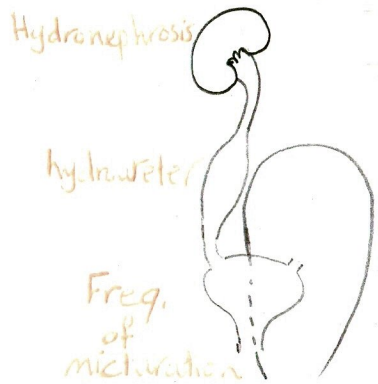

Skin & Breasts :-

Chloasma

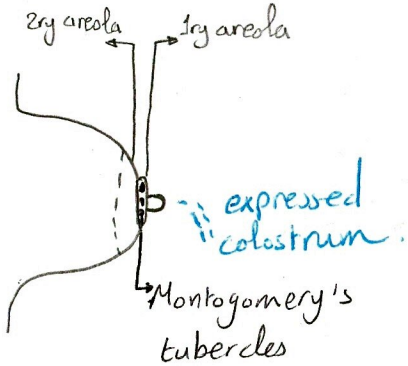

Respiration :-

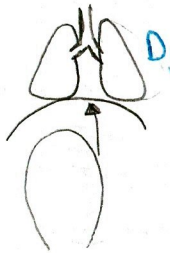

Dyspnea - progest. → hyperventilation.
↑ upward pushing of diaphragm by increasing uterus.

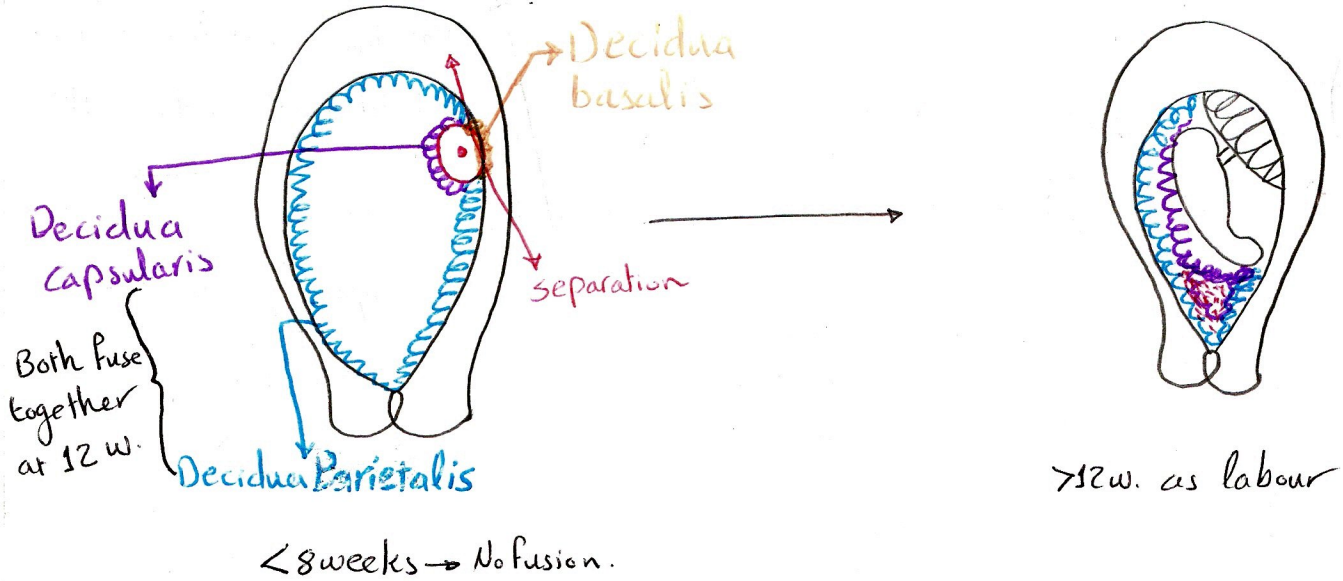

<8weeks → No fusion.

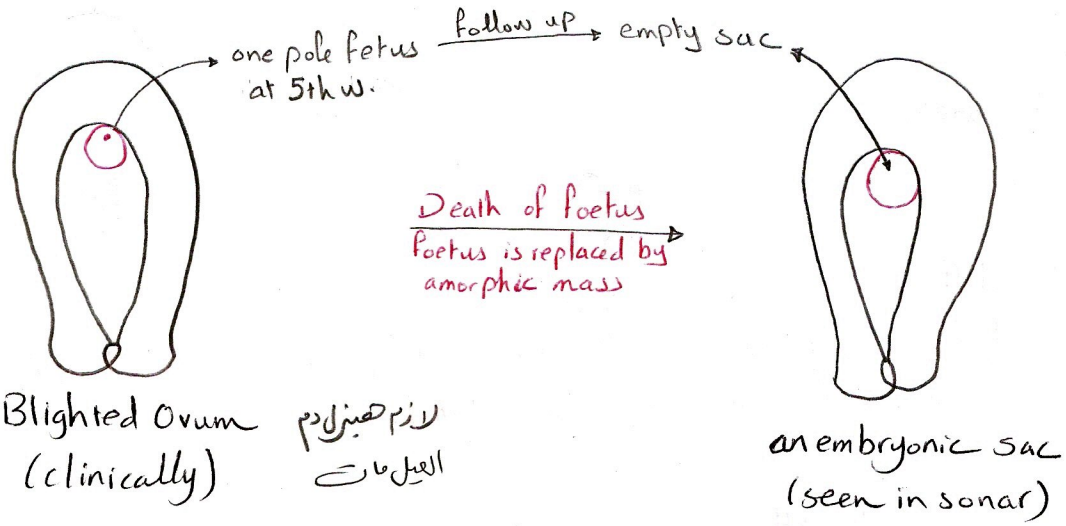

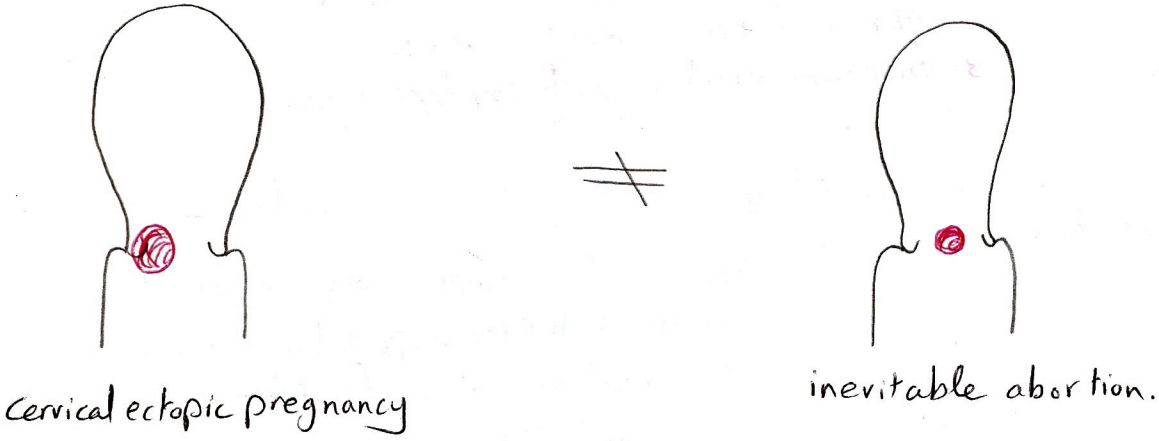

PCis Pessary for { induction of abortion. / induction of labour.

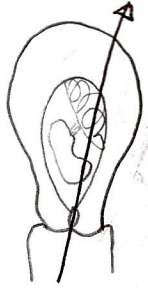

1) infection → soft friable uterus
2) stretched uterus → thin walls

liable for perforation → septic peritonitis

Biarcuate	Septate	Sub-septate
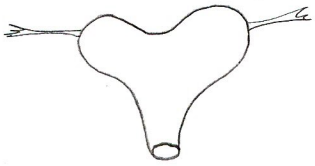		
★ HSG:- Differentiated by angle.		

★ laparoscopy:- - used to differentiate between types.
- Not used alone as you can't see the cavity by laparoscopy (only ext. appearance which is normal in septate & subseptate).

★ accompanied by:-

1- isthmus incompetence
2- abnormal uterine contractions due to abnormal arrangement of ms. fs.
3- Septum interfere with implantation.

★ ttt		
- cerclage - Uterine Reconstruction	- cerclage	- cerclage

Removal of the septum by combined usage of Hysteroscope & laparoscope to avoid uterine perforation.

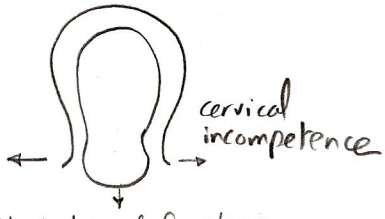

Herniation & Rupture of memb.

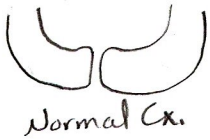

Normal Cx.

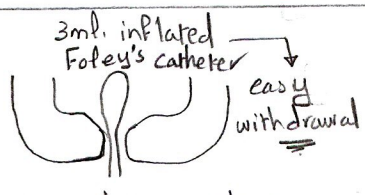

Cervical incompetence (Funnel shaped).

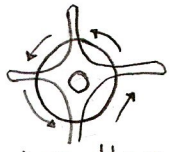

suture Here (sound is placed inside Cx)

suture is made as high as possible

McDonald's operation



incision in ant. lip of Cx. to create tract.

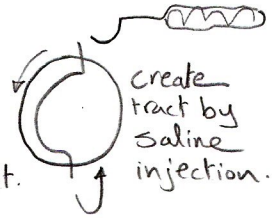

Shirodkar Operation

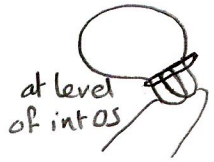

Abdominal cerclage

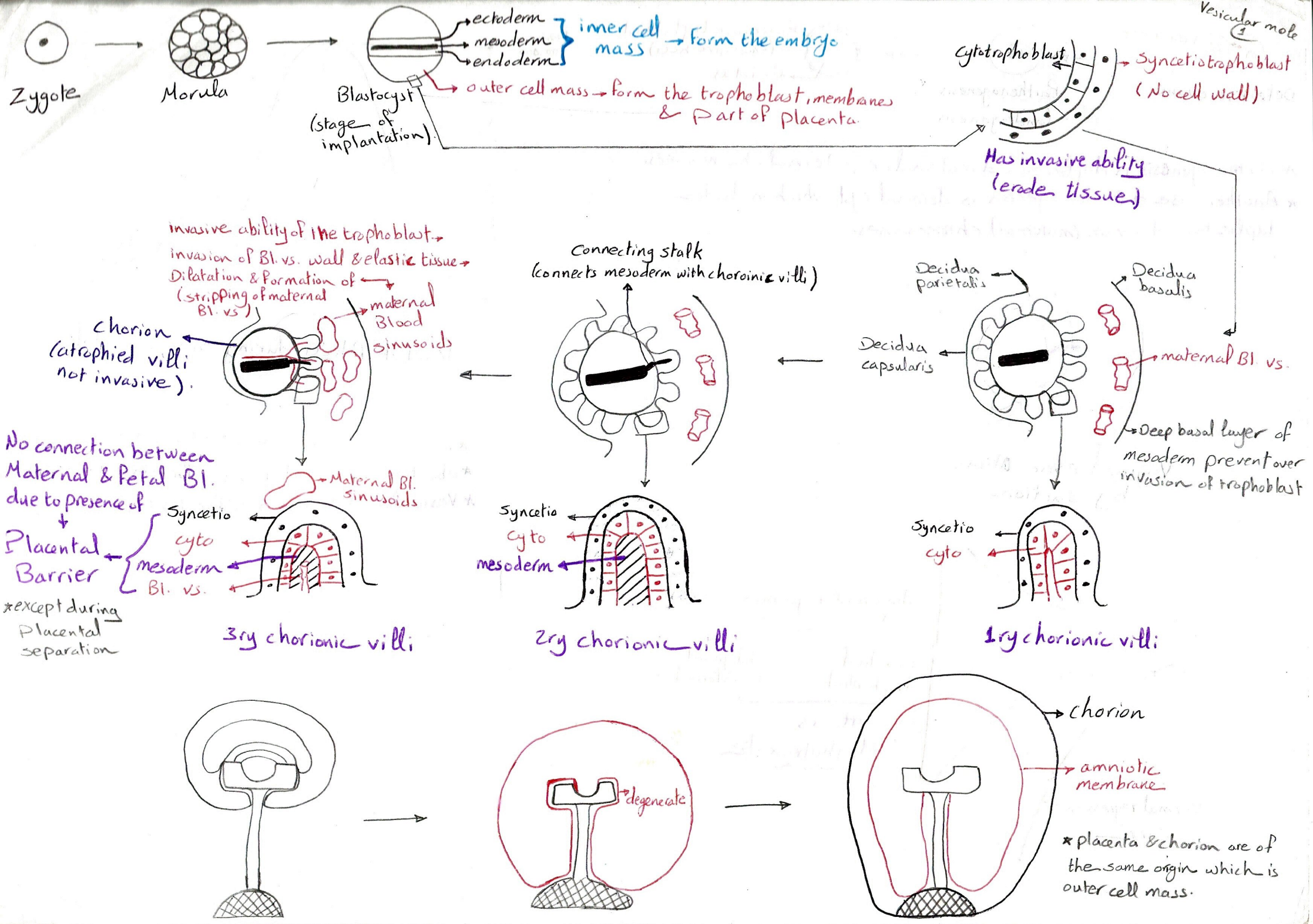
Zygote
Morula
Blastocyst
(stage of implantation)
ectoderm
mesoderm
endoderm
inner cell mass → Form the embryo
outer cell mass → form the trophoblast, membranes & part of placenta
Vesicular mole
Cytotrophoblast
Syncetiotrophoblast
(No cell wall)
Has invasive ability
(erode tissue)
invasive ability of the trophoblast →
invasion of Bl. vs. wall & elastic tissue →
Dilatation & Formation of ←
(stripping of maternal Bl. vs)
maternal Blood sinusoids
Chorion
(atrophied villi not invasive).
Connecting stalk
(connects mesoderm with choroinic villi)
Decidua parietalis
Decidua basalis
Decidua capsularis
maternal Bl. vs.
Deep basal layer of mesoderm prevent over invasion of trophoblast
No connection between Maternal & Fetal Bl. due to presence of
+
Placental Barrier
*except during Placental separation
Maternal Bl. sinusoids
Syncetio
cyto
mesoderm
Bl. vs.
3ry chorionic villi
2ry chorionic villi
1ry chorionic villi
degenerate
chorion
amniotic membrane
* placenta & chorion are of the same origin which is outer cell mass.



Defective ovum → Parthenogenesis (androgenesis →

* Parthenogenesis is duplication of maternal or paternal chromosomes.
* Another case of parthenogenesis is dermoid cyst which include duplication of ovum (maternal) chromosomes.

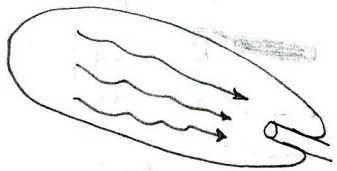

Vaginal evacuation by suction

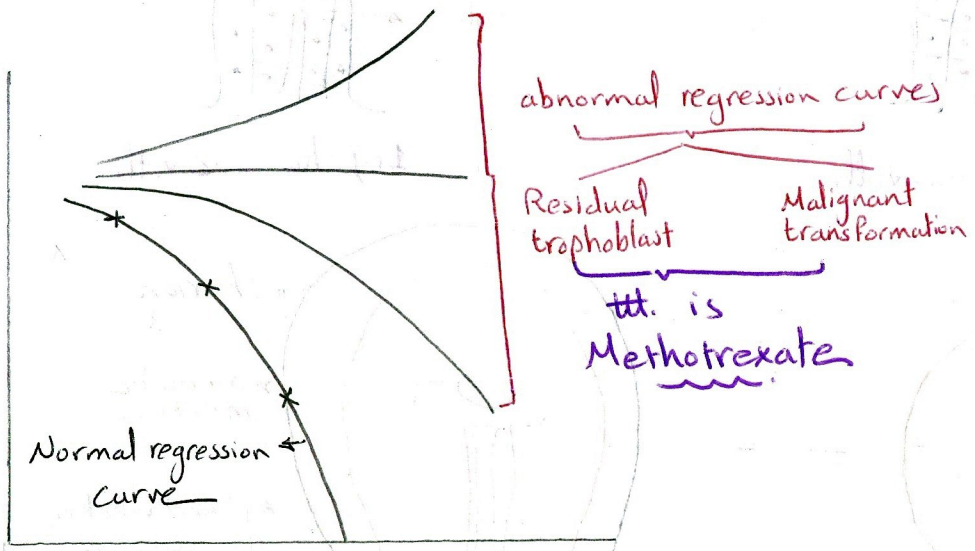

Vesicular mole (2)

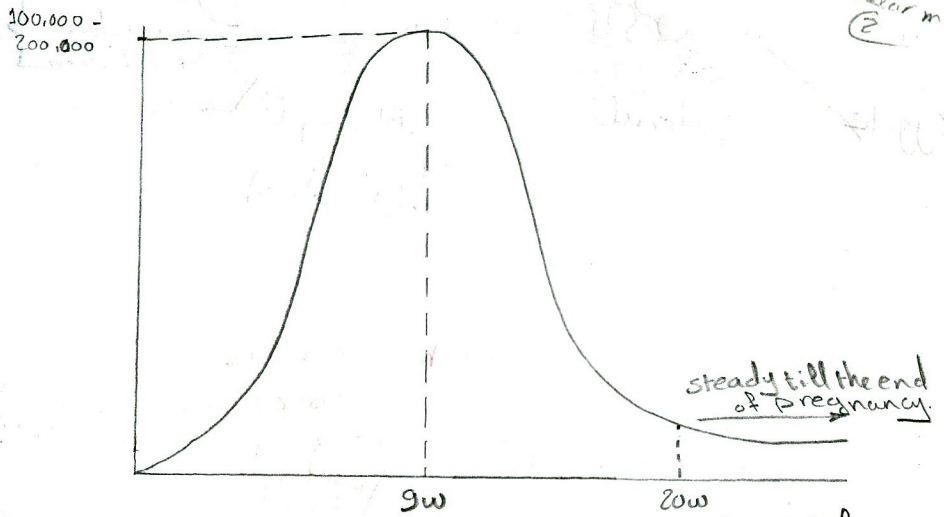

level of BhCG during Vesicular Mole.

* Delivery of pregnant ♀ → 2w for BhCG to disappear
* abortion of pregnant ♀ → 4w for BhCG to disappear
* Vesicular Mole → 8w for BhCG to disappear

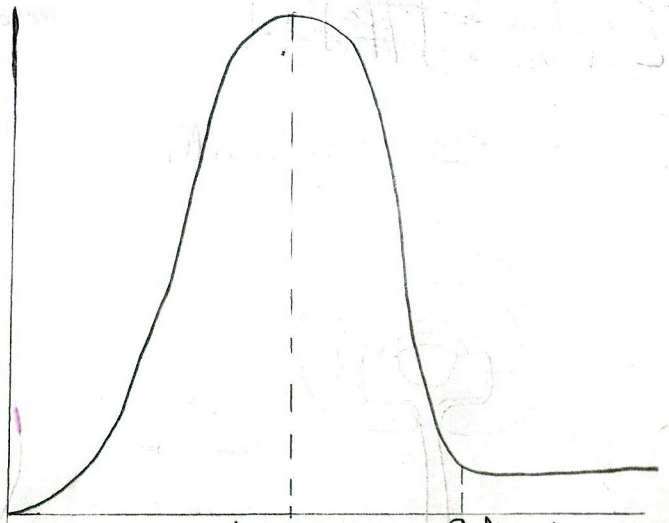

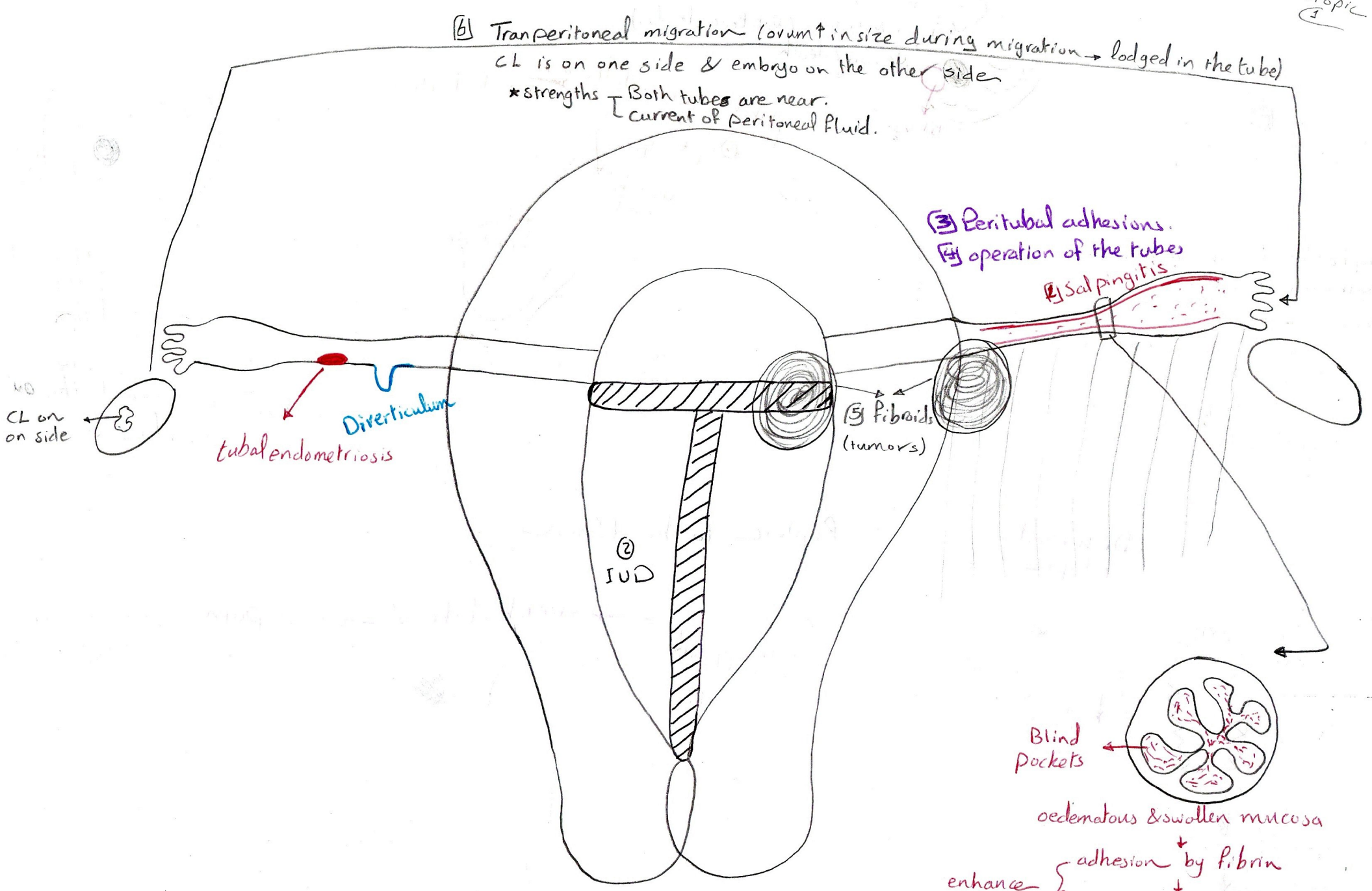

Etiology of ectopic Pregnancy

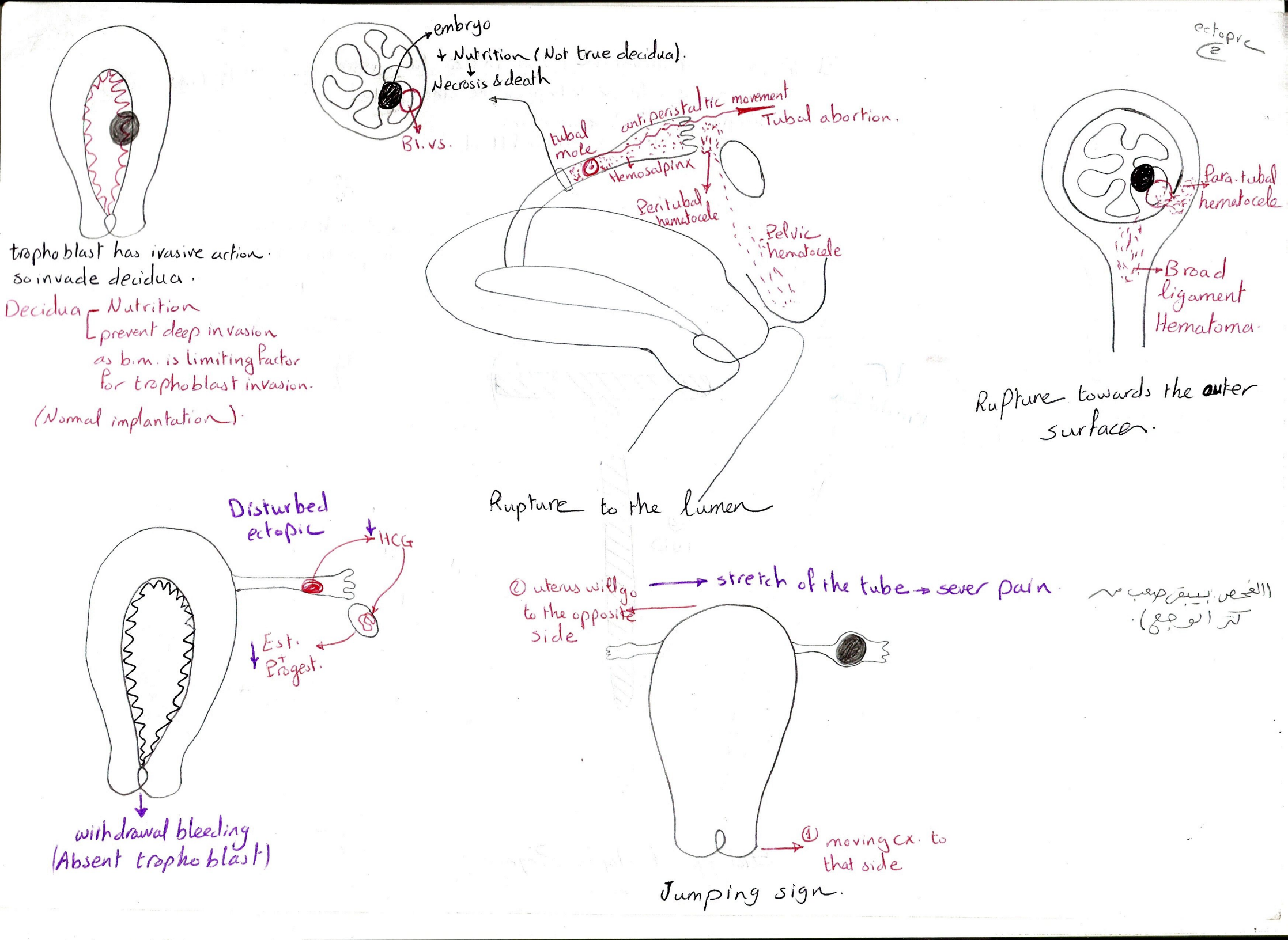
ectopic
2
embryo
+ Nutrition (Not true decidua).
Necrosis & death
Bl. vs.
tubal mole
antiperistaltic movement
Tubal abortion.
Hemosalpinx
Peritubal hematocele
Pelvic hematocele
trophoblast has ivasive action.
so invade decidua.
Decidua
Nutrition
prevent deep invasion
as b.m. is limiting factor
for trophoblast invasion.
(Normal implantation).
Para-tubal hematocele
Broad ligament Hematoma.
Rupture towards the outer surface.
Rupture to the lumen
Disturbed ectopic
HCG
Est. + Progest.
withdrawal bleeding
(Absent trophoblast)
② uterus will go to the opposite side
stretch of the tube → sever pain.
الفحص بيبقى صعب من كتر الوجع).
① moving cx. to that side
Jumping sign.

if the ovary is closely related or adherent to the tube → salpingo-oophorectomy.

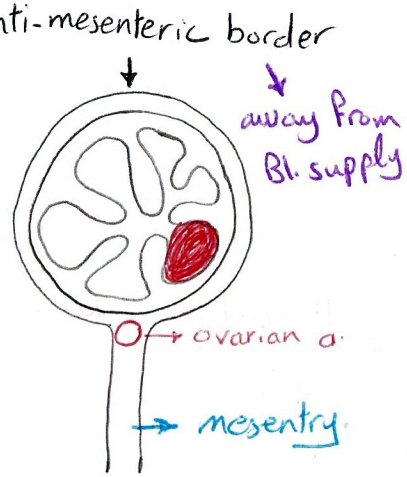

site of incision in salpengostomy

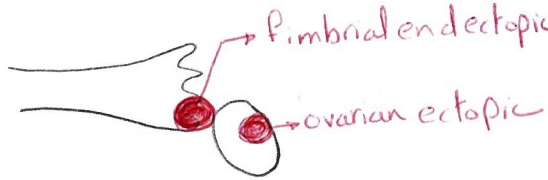

most of doctors say that it's ovarian ectopic but it's fimbrial end ectopic.
So Spiegelberg's Criteria were done to prevent this mistake.

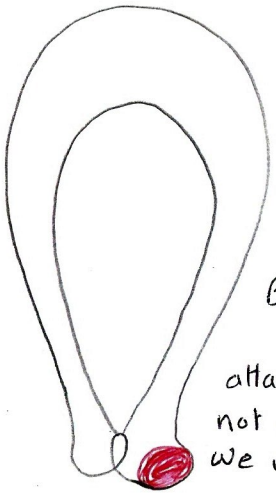

Below the level of Int. OS
attached to cx.
not removed
we use Methotrexate.

cervical ectopic

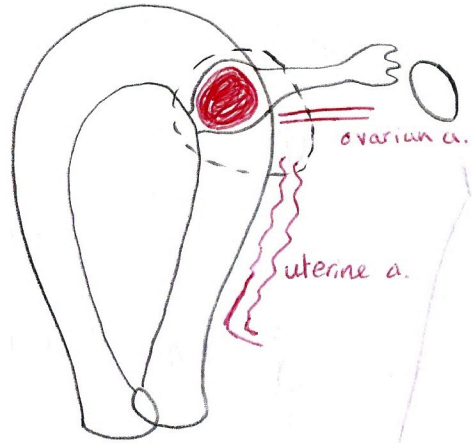

Interstitial tubal ectopic
Rupture at 4th or 5th. m.
ttt. is Hysterectomy.

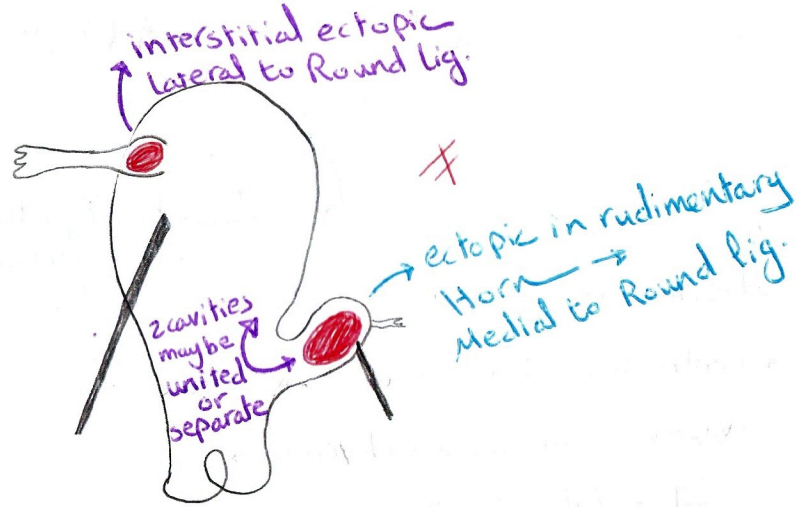

ectopic in rudimentary horn
ectopic as it's outside normal uterine cavity
ttt. is excision of the horn

Normally trophoblast erodes ms. layer & elastic layer of Bl. vs. → Dilatation & formation of maternal Bl. sinusoids.

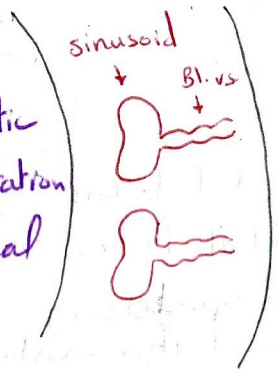

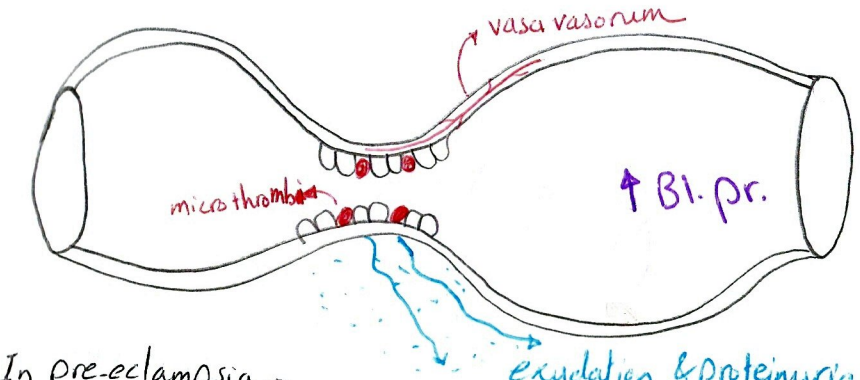

In pre-eclampsia →
abnormal response of Bl. vs. to vasoconstrictors.
→ Contraction of Bl. vs. wall → closure of vasa vasorum → ischaemia →
loss of endoth. integrity → exudation

Hemorrhage & Necrosis of organs.

- subcapsular Hematoma.
- Pulmonary oedema.
- cerebral Hge.
- Exudative Retinal detachment.
- Necrosis & Hge of myometrium.
- Necrosis & Hge of adrenals
- Cortical necrosis.
- Accidental Hge in placenta & uterus.

Bl. constitutes & vascular system.

- ↓ Bl. volume.
- ↑ Hb. conc. relatively.
- Coagulation abnormalities.
- loss of resistance to AgII.
- ↑ Uric acid in Bl.

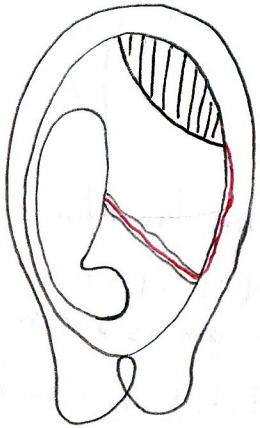

Velamentous Insertion of the cord

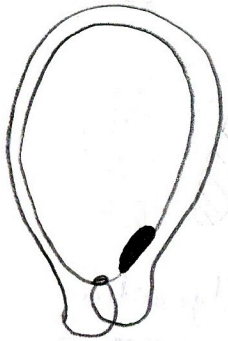

low-lying

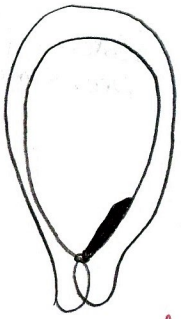

Marginal

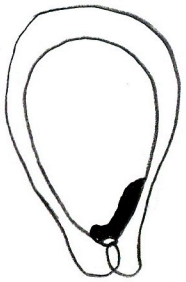

Partial



Total

Degrees of Placenta Previa

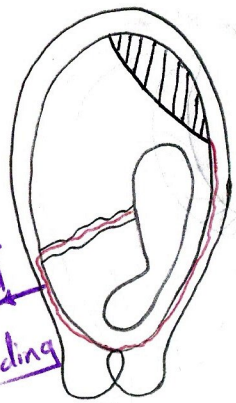

Vessels are Not supported → tearing & bleeding

Vasa Previa

but normally warton gel in the cord support vessels

isthmus 3mm

12 week starting from 28th. week
36 times of stretch

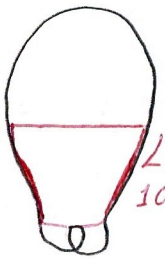

LUS 10cm → From isthmus.

contraction & Retraction

UUS shorter & thicker

↑Pr.

LUS is moved upwards.

LUS longer & thinner

Placenta & membranes are moved downwards } Shearing movements.

thick & short UUS

long & thin LUS

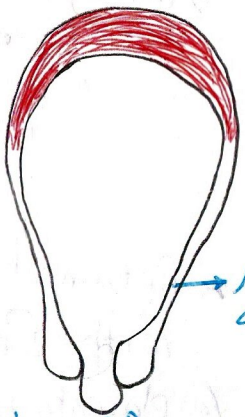

Membranes are loosely attached with LUS

bag of fore water

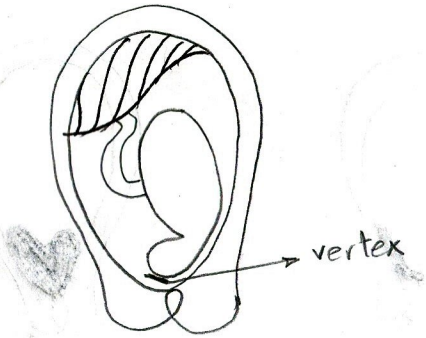

Normal Presentation
(vertex presentation).

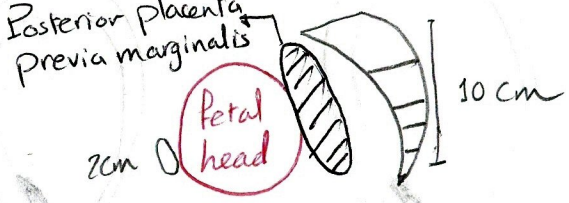

Fetal bradycardia
due to compression
of placenta between
fetal head bones & sacrum

CS is indicated

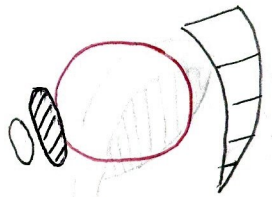

Antepartum Hge

No bradycardia
as symphysis pubis is 2Cm
but sacrum is 10Cm

Vaginal delivery can be done
theoritically.

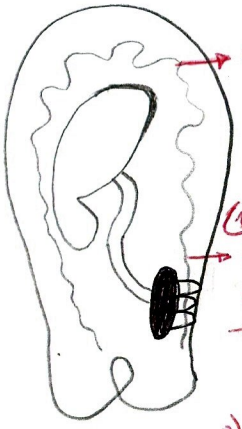

more secretory changes
(thick decidua).

Poor decidua (Sec. changes)
So excess invasion of trophoblast
→ (Retained or incomplete separation
of placenta).

2) thin myometrium → bleeding to inside
due to poor contraction so
we make incision of CS in LUS
to → control bleeding & leaving
strong scar.

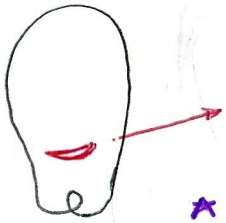

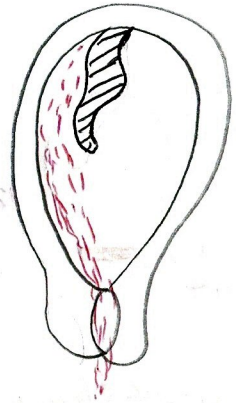

Revealed

Couvelaire's uterus.

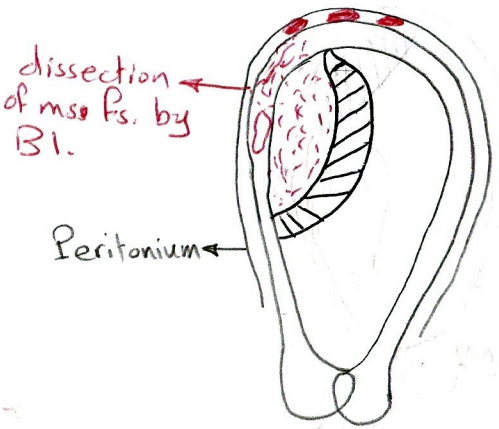

Concealed

* Retained placenta is more common
with Previous CS.
(as placenta is adherent to scar of previous
CS → serious problems with high incidence of Hge).

Scalp

S skin

C CT

A Apponeurosis of ms.

L loose areolar CT.

P Periosteum.

- limited to one bone by periosteum
- Hemolysis → jaundice

Cephalhematoma

1-2 min.

After coming head

Normal wide subpubic angle

Narrow angle
↓
Head is displaced backwards
↓
over distension of perineum.

1st. 2nd. 3rd. 4th.

prolapse occurs with 2nd. degree

No prolapse occur as stool & flatus incontenence make patients do continuous cont. of levator ani → hypertrophy of the ms → ↓ prolapse.
العيانة ماسكة نفسها

incomplete perineal tear (1st, 2nd) — complete perineal tear (3rd, 4th)

* كرينا العيل يعني لازم نكبر الـ episiotomy

* if baby is preterm do episiotomy even if he has small head to prevent chance of sudden compression & decompression (مايتعملش).

fixed point

Post. buttock exit 1st by lat. flexion of the spine

large episiotomy is needed to avoid injury of vertebral column.

* Sutures
- non-absorpable → silk & Nylon.
- absorpable
  - Rapidly or slowly absorbed.
  - Monofilament or polyfilament.

- size 4 3 2 1 0 00 (2/0) 000 (3/0)

Continuous
- Better hemostasis → compress vs.
- Rapid

* but may shorten the wound (يكرمش)

* interrupted is preferred in infection as if one suture is infected & will undergo lysis
أهي غرزة واحدة مش الخيط كله

Bl. Group :-

A	Ag-A	Ab-B	D-Ag.
B	Ag-B	Ab-A	Rh^+ 85%
AB	Ag-A, Ag-B	No Ab.	
O	No Ag.	Ab-A, Ab-B	Rh^- 15%

A & B antigens present in nature in food, air, pollens, ---etc.
so Bl. contain their Ab.

D antigen isn't present in nature
So no Antibodies for it.

★ Sensitized ♀ :- has Ab for D antigen either from Bl. transfusion of Rh^+ Bl. or from previous preg.

♂ +ve
♀ -ve

homozygos +ve → +ve
heterozygos +ve → -ve
-ve → -ve

Fetus +ve
+ve -ve
↓
Placental separation
↓
Mother becomes sensitized by IgG
↓
cross placenta to 2nd. fetus (if Rh^+)
Hemolysis
↓ RBCs :-
- Fetal anaemia
- Intrauterine HF
- generalized oedema (hydrops fetalis)
- ascites
★ accelerated production of RBCs.
↑ Bilirubin → Drained by Placenta.

after delivery →
Fetus can't excrete All amounts of Bilirubin →
- Neonatal Jaundice
- Pass BBB & deposite in Basal Ganglia → kernicterus.

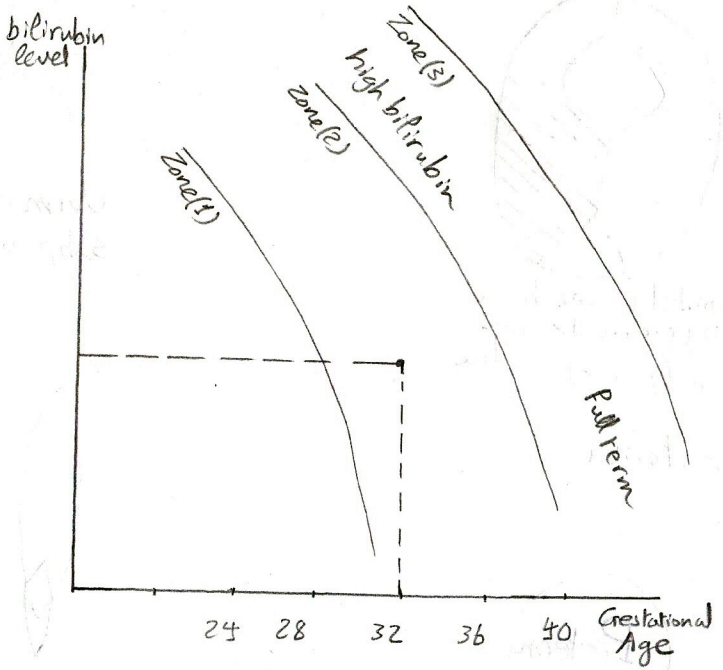

Liley's curve

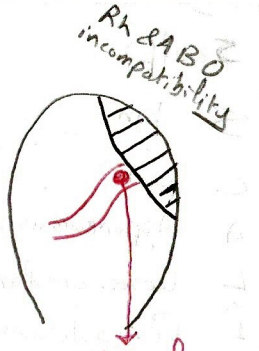

site of cordiocentesis (most fixed part)

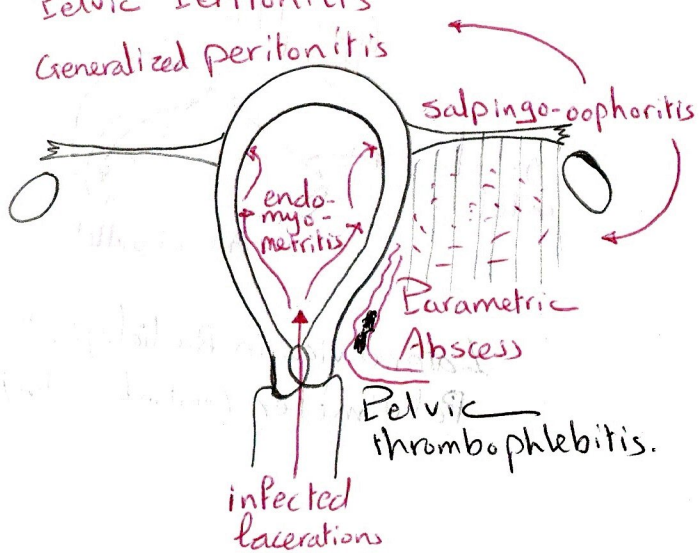

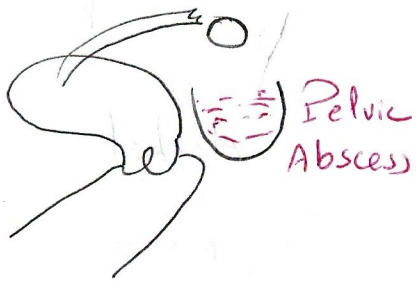



Fowler's Position.

Contracted pelvis

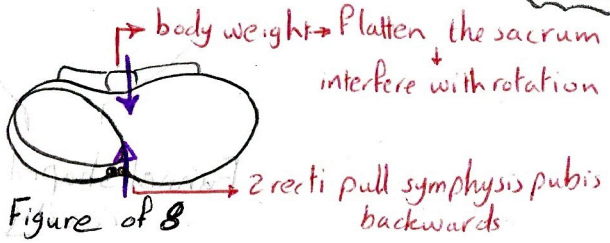

Figure of 8

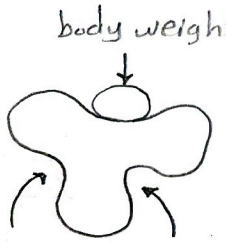

triradiate or trifoliate pelvis

الست تولد وتخلف كتير وما تتعرضش للشمس

↓

osteomalacia (demineralization of bones)

osteomalacia must be severe to make this exaggerated form

Rickets
- everted ischial tuberosity (مكان الجلوس) (wide outlet) لأن السن صغير والبنت لسه من بتمشي
- Promontry is pushed forwards & symphysis pubis is pulled backwards. (contracted inlet).
- Head
  - AP diameter in tv. diameter of pelvis
  - enter by superparietal subparietal diameter (asynclitism).
  - pushed to lateral pelvic wall.

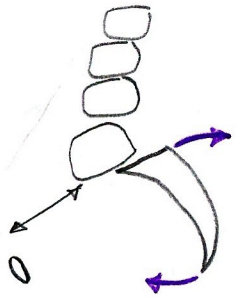

Spondylolisthesis

outlet contraction

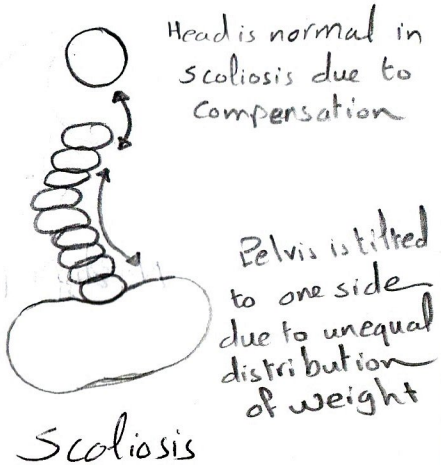

Scoliosis

Etiology of contracted pelvis

contracted pelvis

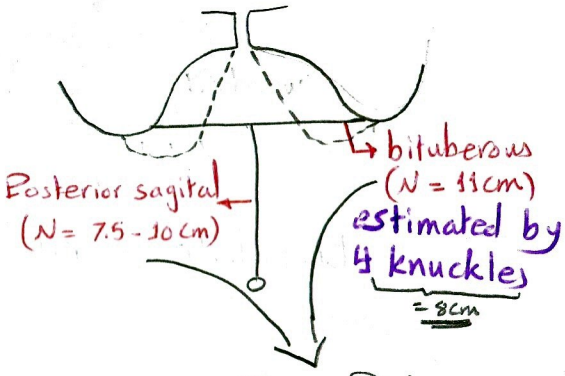

Thom's Dictum

bituberous (>8cm) + posterior sagital

> 15cm

Funnel shaped pelvic cavity

Diagnosed by palpation of pelvic side walls

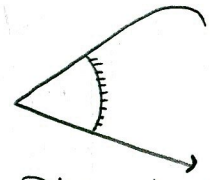

Pelvimeter

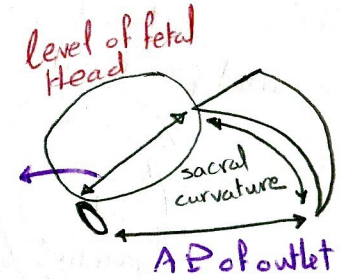

Lateral view in Radiological Pelvimeter (most informative).

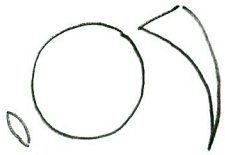

No disproportion

Normal vaginal delivery if CS isn't indicated



Minor

True conjugate 9-10cm

Normal vaginal delivery if CS isn't contraindicated



Moderate

8-9 cm

Trial of labor if failed

↓

CS



Marked

6-8 cm

CS

Extrem <6cm

Diagnosis & Management of obstructed pelvis

* obstructed labor is considered as a less common cause of Rupture uterus → CS ← لذلك اللي مش عارف ولقرا الولادة طولت

* Cx tear extending to uterus is the commonest Now
  → in the past was commonly caused by wrong application of the forceps before full cervical dilatation.
  → Nowadays it's caused by wrong use of ecbolics:
  (PCTs) on tablet contain 200 µg of misopristol (ttt for GIT dis.) it causes cervical ripening if used by a proper dose which is 25 µg & left for 4-6 hrs.
  * if used by over dose or not left to work for a proper time will make cx open but it will be so friable (اتقرح عليه بعد الولادة)
  → sever Postpartum Hge & may be cx tear → Rupture uterus.

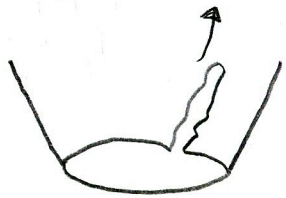

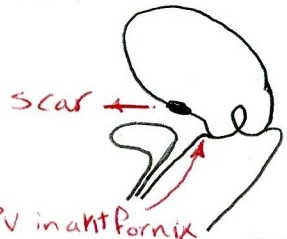

PV in ant fornix to assess tenderness of the scar.

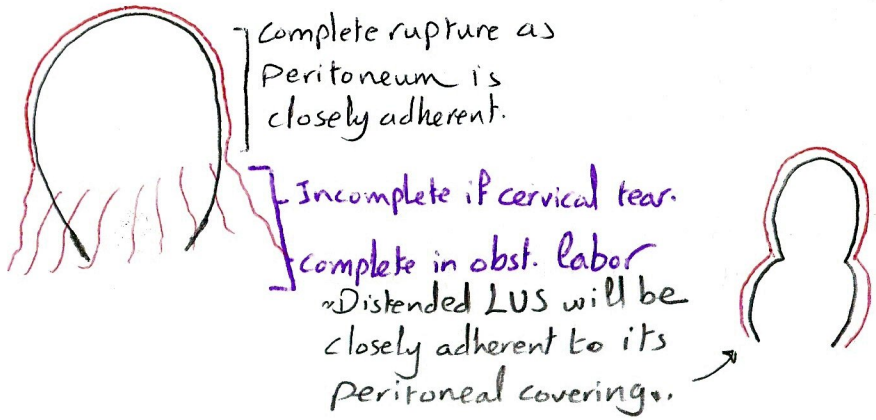

- complete rupture as Peritoneum is closely adherent.
- Incomplete if cervical tear.
- complete in obst. labor
  ~Distended LUS will be closely adherent to its peritoneal covering..

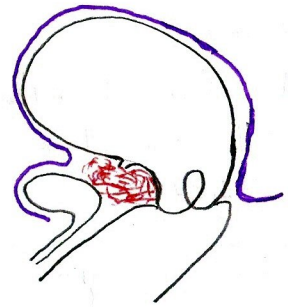

Painful tender fullness at suprapubic region due to accummulated Bl.

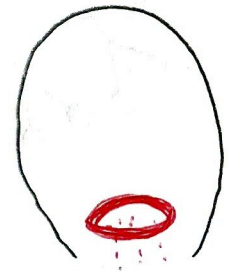

- Minimal Bleeding due to fibrosed edges
- No extension due to fibrosed edges.

Silent Rupture.

cervical lacerations

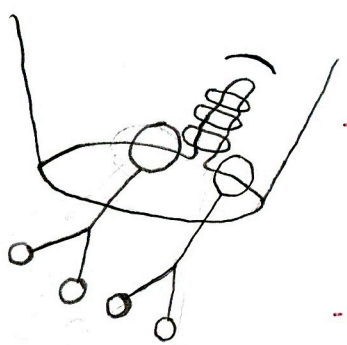

- 2 ring forceps to avoid cx injury
- identify apex of the tear
- نحرك واحد ورا الثاني
  12 → 2
  2 → 4
  4 → 6
- 1st. suture above the apex
- We take 3-4 sutures as cx is 2-3 cm.

Don't make sutures at edges of the tear as cx is very friable → more damage.

if away from edges → cx will roll in تلف لجوة.

Interrupted Matrus sutures
- No damage to cx
- Proper apposition of edges
- Hemostatic as cx is plicated & compress Bl. vs

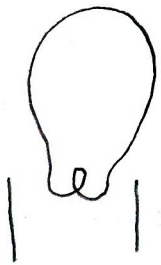

colporrhexis
(Rupture of vagina).



- Fetal monitor is programed & calculate FHR according to distance bet. peaks
- FHR has beat to beat variability pattern ↑ &↓ due to ↑ sympath. for some time & ↑ parasympath for for some time (كرة فوق وكرة تحت)

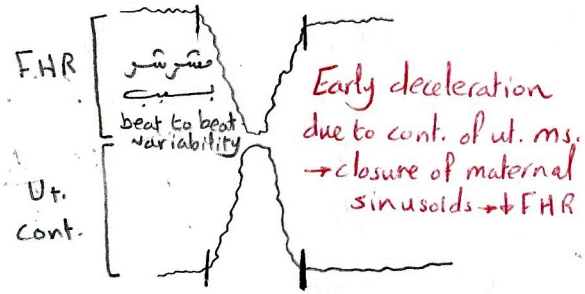

Early deceleration
due to cont. of ut. ms. → closure of maternal sinusoids → ↓ FHR

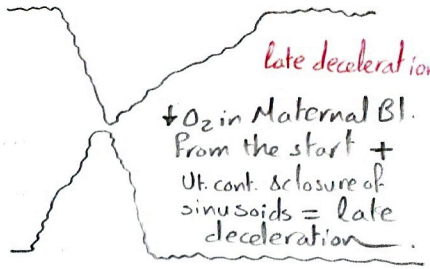

late deceleration
↓ O_2 in Maternal Bl. From the start + Ut. cont. & closure of sinusoids = late deceleration.

* أحسن وقت نسوي منه نبض الجنين هو immediate after contraction of the uterus to detect late deceleration

asphyxia

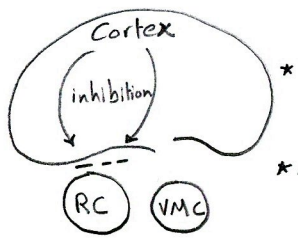

* sporadic Respiration in fetus → inhalation of amnion → Help surfactant distribution
* Mild hypoxia during preg. inhibit cortex so release RC From inhibition → RC ready for action
  ⇒ light, touch, noise → fetal stimulation of Resp.
* Moderate hypoxia → ↓↓ RC → asphyxia neonatorum.
* severe hypoxia → ↓ VMC → dilatation of Bl. vs due to loss of tone → state of shock.

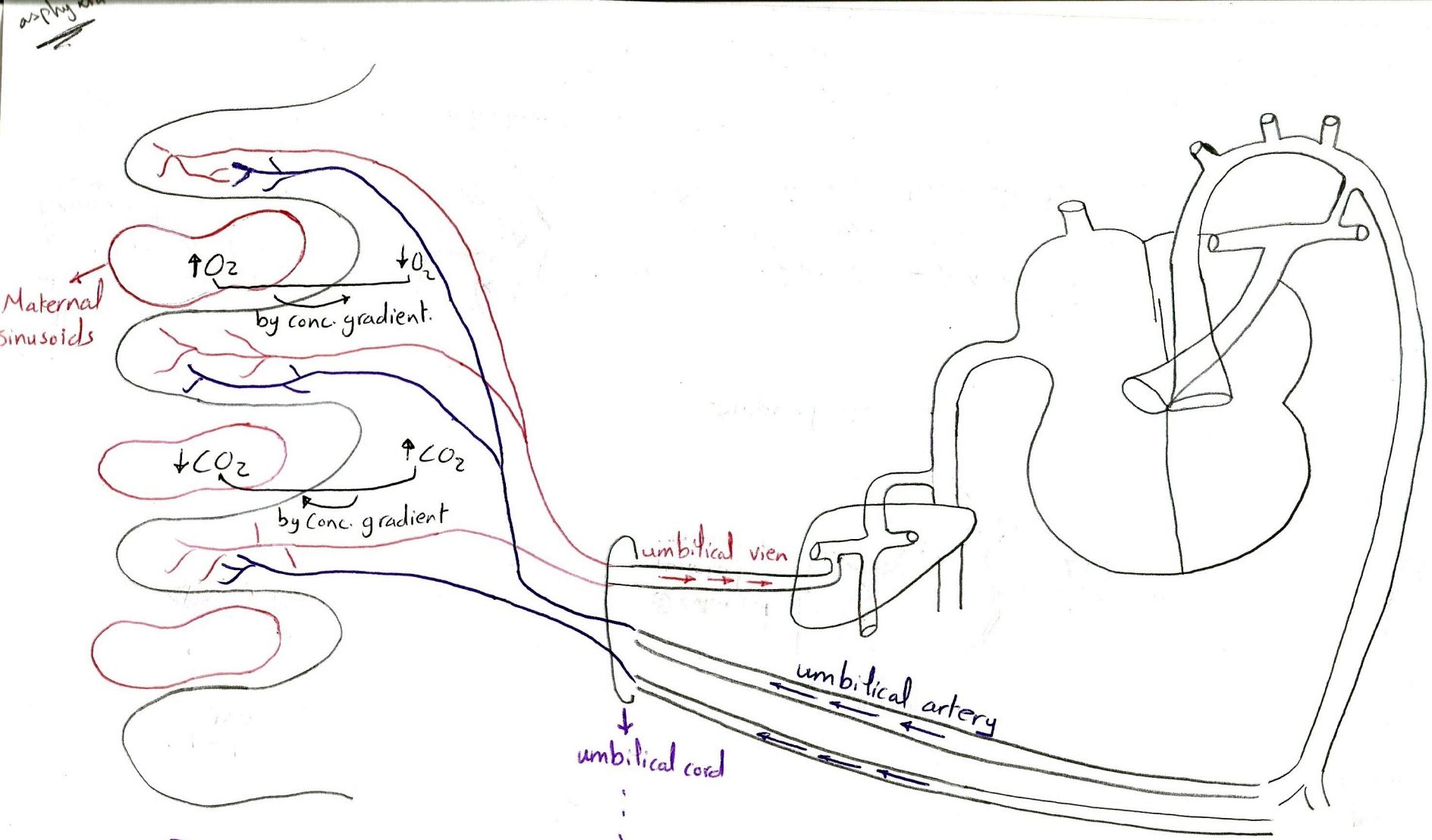

Placenta

Placenta

separation

compression

insufficiency

Maternal

IF

Utm. disease

naemia

ypotension

lampsia

umbilical cord

- compression
- true knots
- tight coils around neck
- Rupture vasa Previa
- Hematoma of the cord

Fetus

compression of fetal Head

- ↑ vagus → ↓ FHR
- ↓ fetal RC

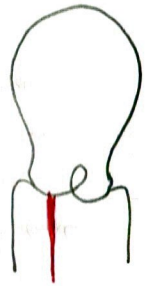

Longitudinal vaginal septum



Impacted fibroid

Indications of CS

Paramedian incision

old procedure → incision for many things:-
e.g. appendicectomy, removal of ovarian masses --- etc.

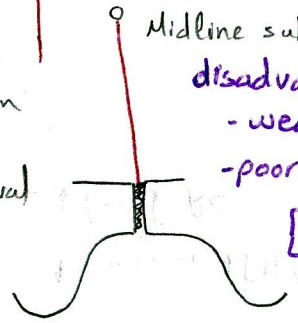

Midline subumbilical incision:

disadvantages:-
- weaken the area → surgical hernia
- poor healing due to:-
  [↓ Bl. supply
  [traction on incision by ms.
- poor shape due to disturbance of subcutaneous collagen fs.

CS

incision should be parallel to collagen fs. arrangement.

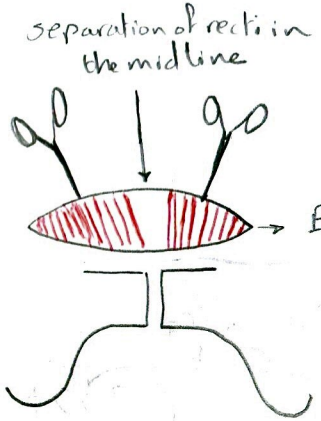

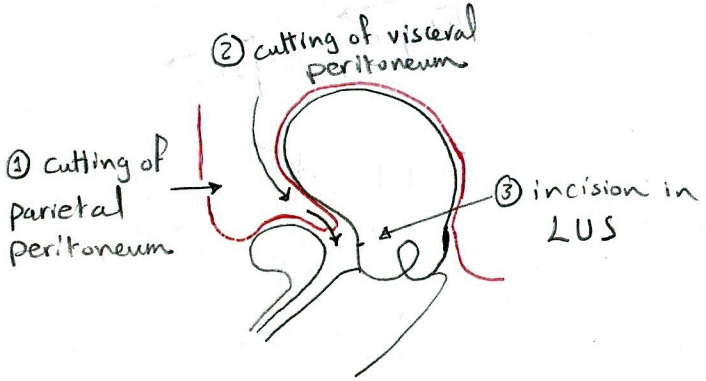

Steps of CS

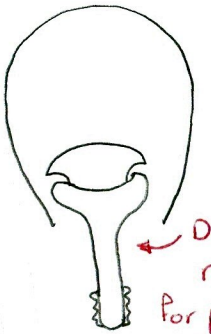

infection with UUS CS → peritonitis which is very dangerous (50% mortality) as peritoneum is firmly adherent to UUS

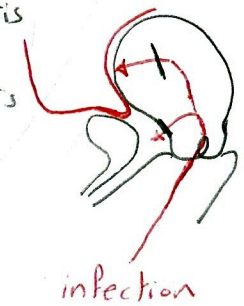

infection in LUS CS → parametritis which is less dangerous than peritonitis → So LUS CS + peritoneal affection.

Infections (1)

* Most of infections are acute
* Chronic in
  - Menopause
  - IUD
  - T.B. in young ♀

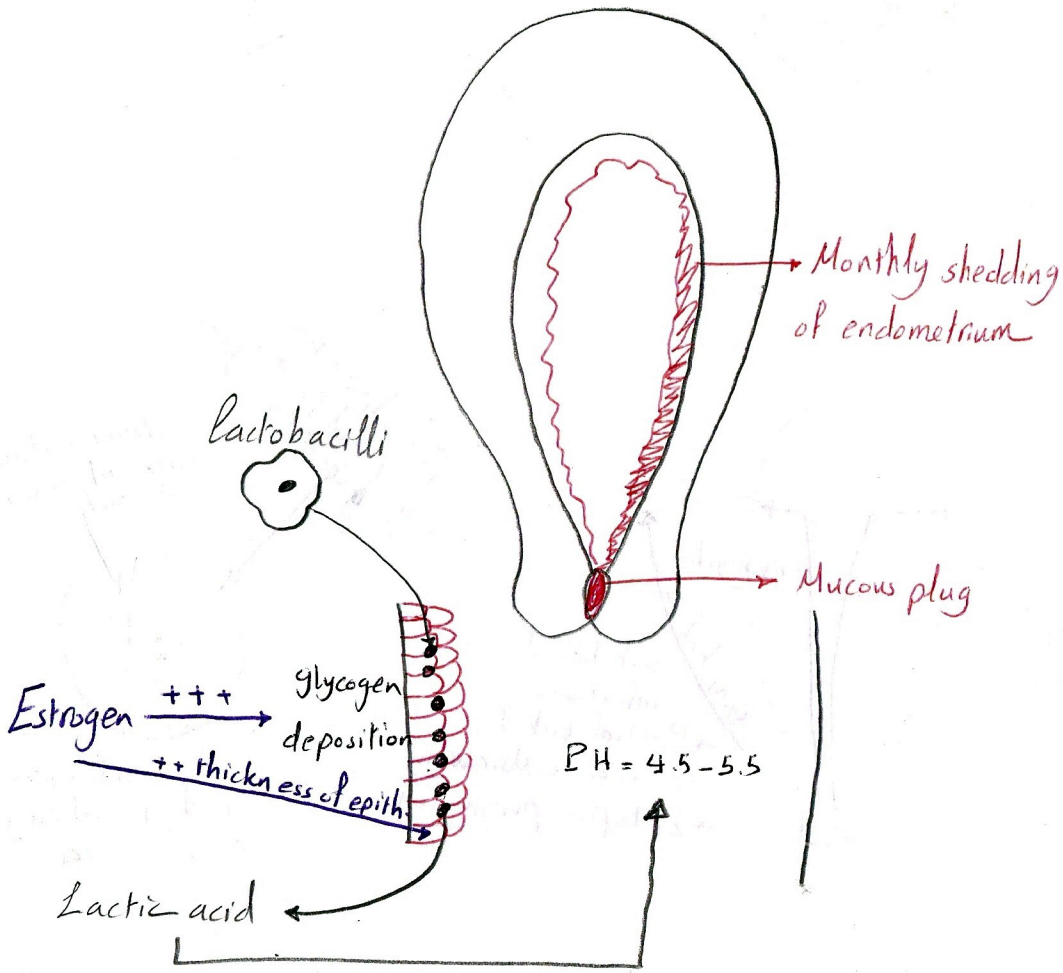

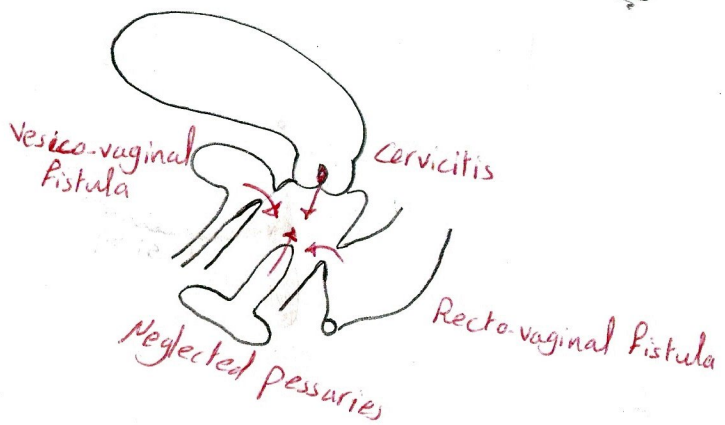

2ry. Vaginitis



childhood
Menopause } ↓ Est. → ↓ acidity

Pregnancy < ↑ Est. / disturb CHO metabolism → ↑ glycogen deposition } ↑ Acidity

DM → Disturbance of CHO Metabolism → ↑ acidity

Infections 2

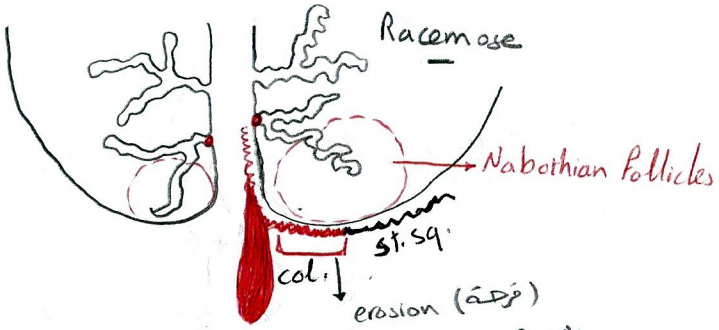

erosion (قرحة)
"wrong name"
as it's covered by col. epith.
which is thin so shows underlying
Bl. vs. → Red area.

Speculum →

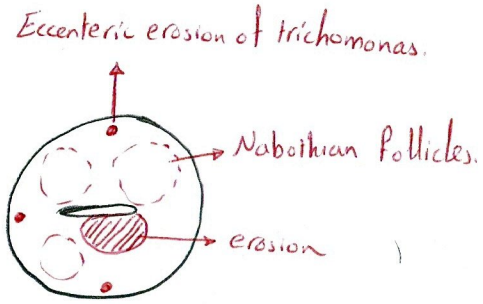

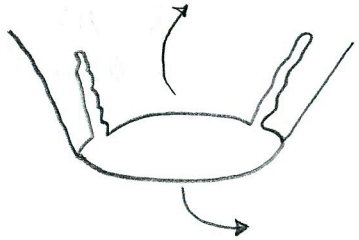

Ectropion.

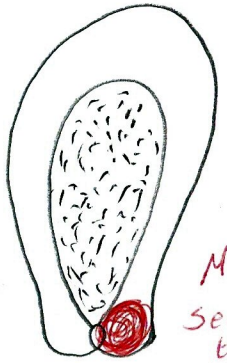

Malignancy
senile atresia of the cervix
↓
Pyometra.

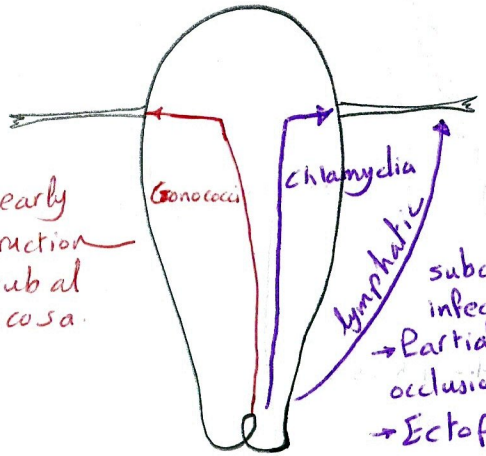

early destruction of tubal Mucosa.

subclinical infection
→ Partial tubal occlusion & Narrowing
→ Ectopic pregnancy

Perisalpingitis with spread from Neighbouring organ.

Interstitial with Bl. or lymphatic spread.

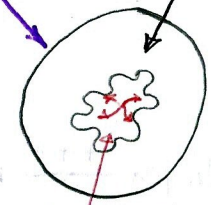

endosalpingitis with gonorrhea & chlamydia

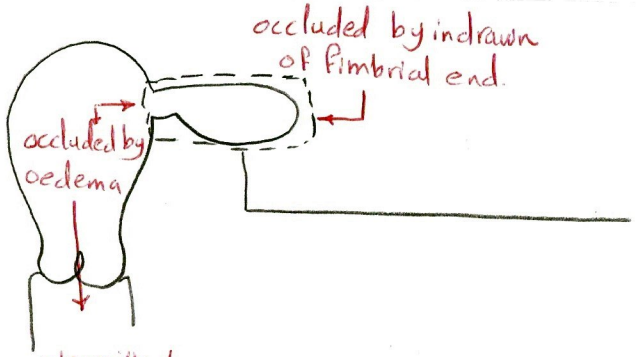

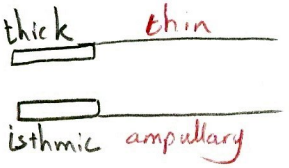



Downwards enlargement > upwards enlargement due to limitation by broad lig.

Infection

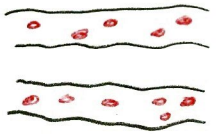

Multiple Micro-abscesses
↓
hypertrophy of tubal walls
"Interstitial salpingitis"

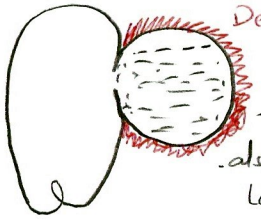

- may be trabeculated
- also some are of huge size larger than uterus itself
- may be bilateral.

Tubo-ovarian abscess

To investigate:-
1. Ultrasonography
2. CT
3. HSG →

Hydrosalpinx



Pyosalpinx

4. laparoscopy:-
- Diagnostic:- salpingitis or endometriosis.
- therapeutic:- salpingostomy & lysis of adhesions.



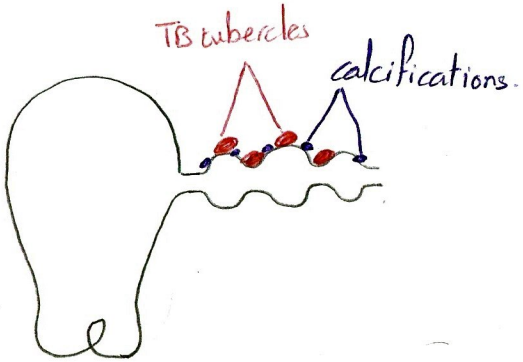

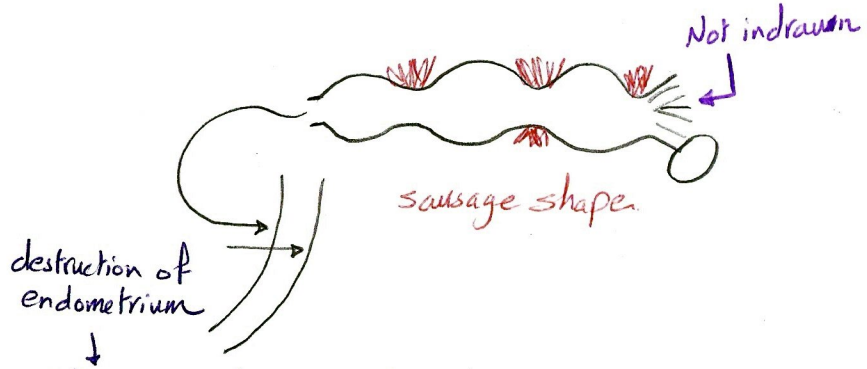

↓
Adhesions → Netter Syndrome.



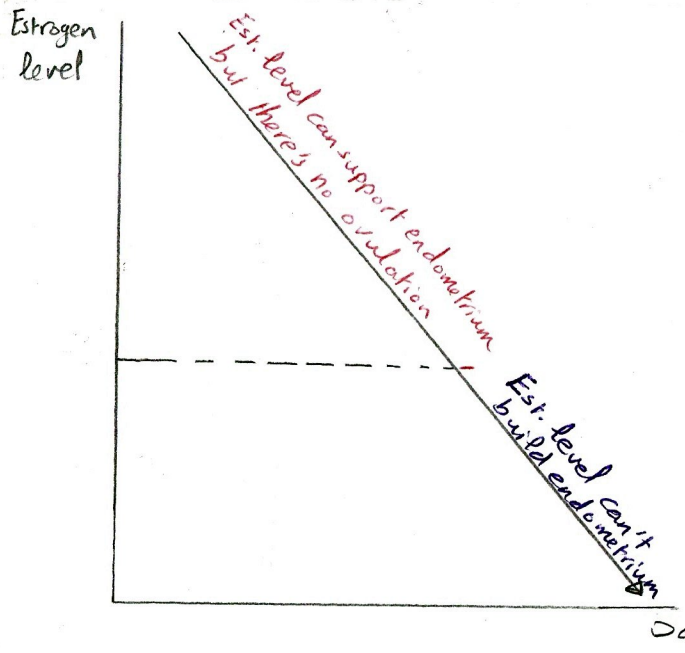

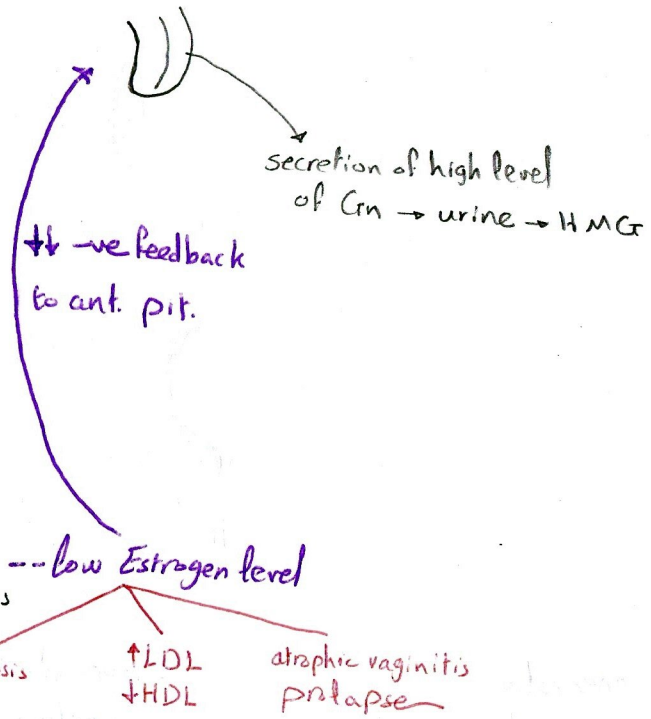

Menopausal changes

Vulva



anatomy of Bartholine gland.

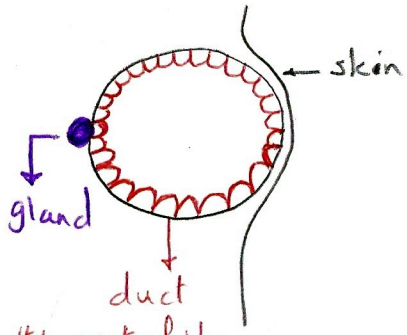

it's cyst of the duct as it's lined by transitional epith. Not glandular.

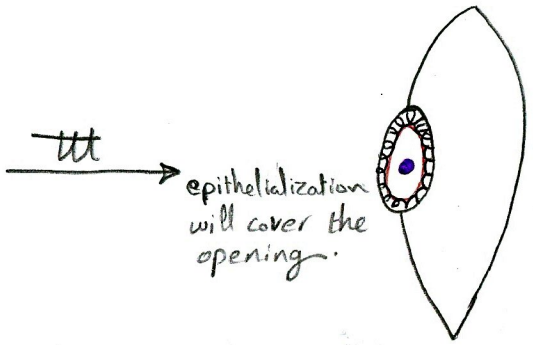

Marsupialization

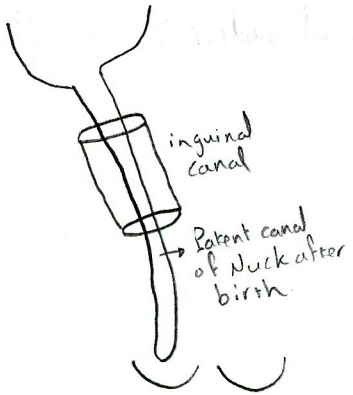

Hydrocele of Canal of Nuck

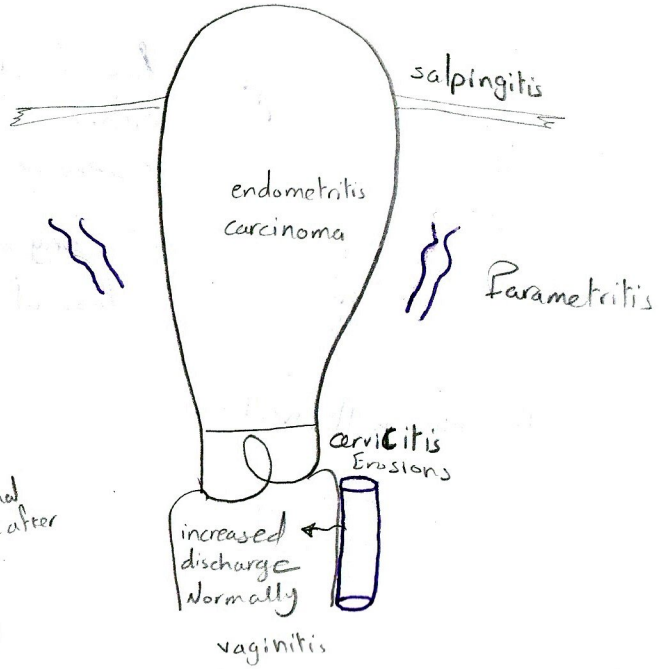

vaginal discharge

U.B. Pr.

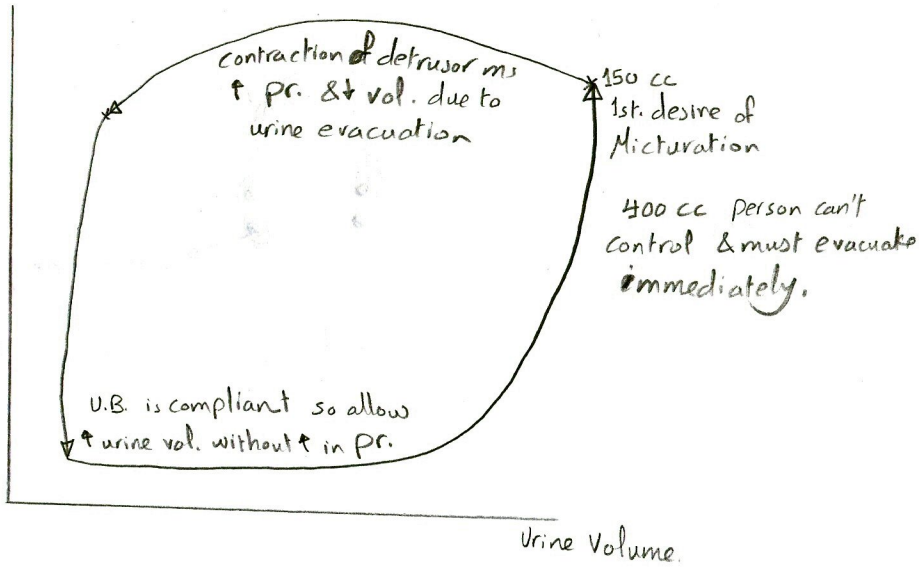

Fistula (1)

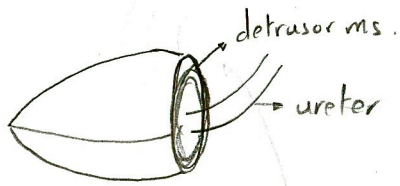

U.B.

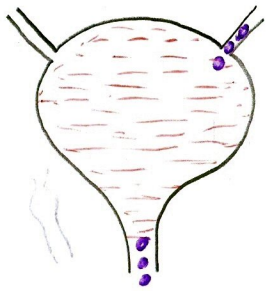

Retention with overflow

- loss of UB innervation
  either motor → No detrusor cont.
  or sensory → No sensation of full UB
- So any drop of urine will enter UB will cause involuntary loss of a drop at urethra.
- over distended UB can't allow urine to return to ureters as ureters are obliquely embedded in the ms wall of UB

Doctor made 2 mistakes
1- UB injury
2- No detection & repair of injury.

Prevention:
1) 1ry. → avoid UB injury
2) 2ry. → repair injured UB



total Hysterectomy

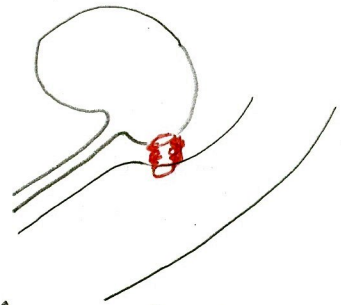

Anterior colporrhaphy



forceps application with full UB (thin).

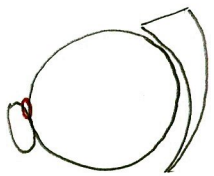

Necrotic obstetric fistula "obstructed labor"

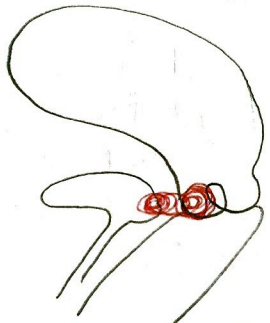

Malignant Fistula from uterus or UB

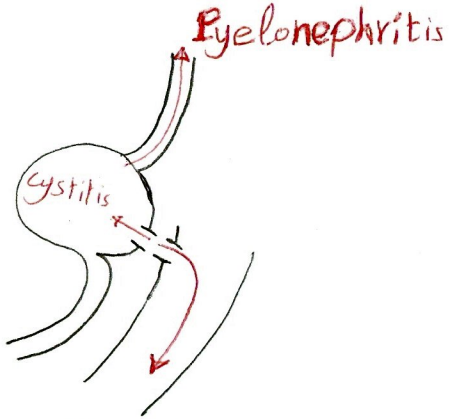

Dry vaginitis
phosphatic encrustations

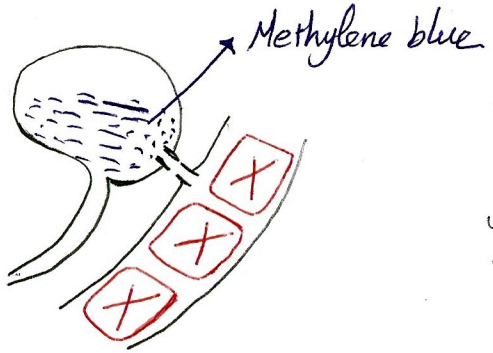

Methylene Blue test

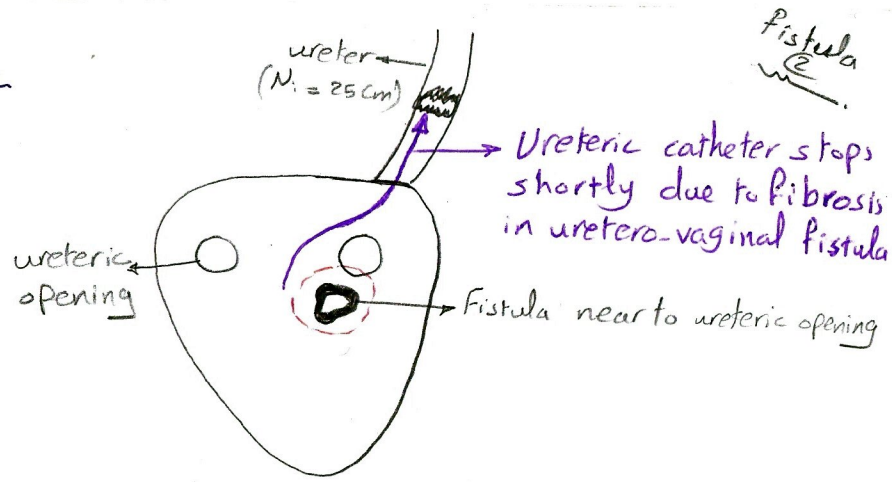

Cystoscopy

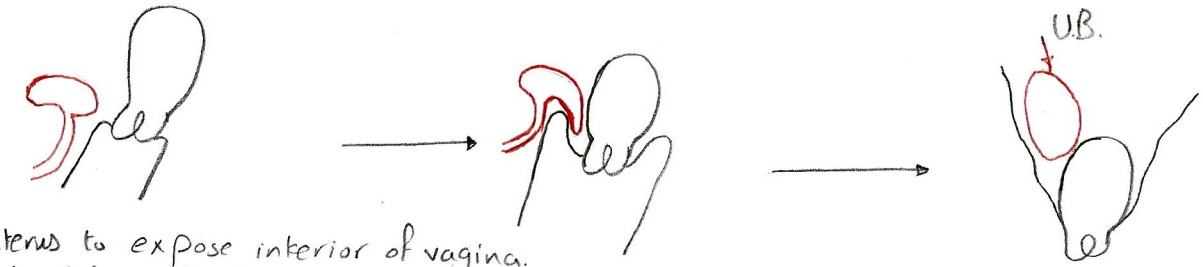

- We pull uterus to expose interior of vagina.
- This is helped by GA which relax pelvic ligaments.
- overstretch → prolapse - Can't be done in previous hysterectomy.

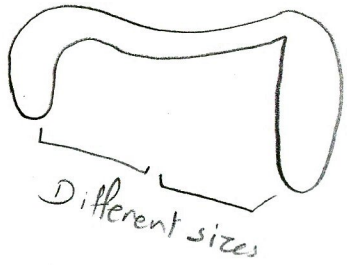

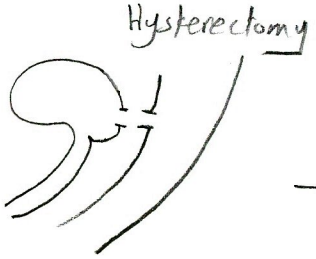

Latzko →

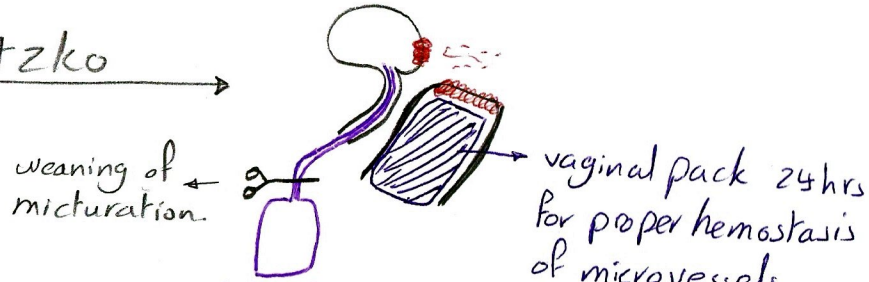

catheter for 10-14 days to avoid UB distention by urine